

Microvascular Free Flap Failure Caused by Unrecognized Hypercoagulability

Steven P. Davison, D.D.S.,
M.D.

Craig M. Kessler, M.D.
Ali Al-Attar, M.D., Ph.D.

Washington, D.C.

Background: Microvascular free flap techniques have improved over the past two decades such that flap failure rates have dropped to under 3 percent in most large series of high-volume centers. However, despite technical and patient-selection advances, some components of free flap failure might be attributable to undiagnosed patient factors.

Methods: In this clinicopathologic conference article, the authors present four patients with major free flap microvascular complications who were later diagnosed with multiple risk factors for hypercoagulability and biochemical abnormalities, and present the characteristic associated findings.

Results: Previously undiagnosed hypercoagulability was present in four patients with major free flap microvascular complications. Hematologic consultation and laboratory investigation revealed the biochemical abnormalities.

Conclusions: In certain patients undergoing microvascular free flap reconstruction, undiagnosed hypercoagulability risk factors can be a source of free flap failure that is independent of patient selection or technical factors. Diagnosis, management, patient counseling, and initiation of deep venous thrombosis prophylaxis measures are critical clinical components of care of these patients. (*Plast. Reconstr. Surg.* 124: 490, 2009.)

Microsurgical reconstruction has become progressively more successful. From the early microvascular flaps to current perforator flaps, the success rate has increased from 63 percent to 98.8 percent at centers of excellence.¹⁻⁵ Despite greater experience, improved technology, and development of anastomotic devices, the average failure rate has not dropped below 1 to 3 percent. The failure rate falls with superspecialization to one flap (deep inferior epigastric perforator flap), improved patient selection, and consistency of surgeon, yet it is not zero.

Although the vast majority of studies of free flap failure allude to technical causes of thrombosis, there are some cases in which the patient is the contributing factor to flap failure.^{3,6-9} One of the hidden contributing factors is undiagnosed coagulopathy.^{9,10} We present four cases in which multiple free flap failures were a direct result of underlying hidden patient predisposition to developing hypercoagulability complications. We discuss the cases, findings, and pathophysiology to

illustrate this process. The most problematic aspect is that the first presentation of coagulopathy might be microvascular complications of the free flap. We also discuss laboratory evaluation of the patient and long-term implications for deep venous thrombosis prophylaxis.

The coagulopathies that are represented in our case series range from relatively common to rare. Many of these coagulopathies are described by their genetic mutation and genetic load (homozygous versus heterozygous). Of critical importance is the concept that, as in much of medicine, flap failure is often multifactorial such that underlying coagulopathy might serve to either cause or predispose to microvascular anastomotic thrombosis.

CASE REPORTS

Case 1

A 43-year-old white woman with a previous wide resection of the cheek and orbital exenteration for lacrimal gland tumor presented with an ethmoid sinus fistula. Sinusectomy and wider excision of the orbit required soft-tissue filling. A superficial inferior epigastric artery free flap to the superficial temporal artery and vein anastomoses was attempted, which resulted in

From the Department of Plastic Surgery and the Division of Coagulation, Georgetown University Hospital.

Received for publication October 8, 2008; accepted February 27, 2009.

Copyright ©2009 by the American Society of Plastic Surgeons

DOI: 10.1097/PRS.0b013e3181adcf35

Disclosure: None of the authors has any financial conflicts of interest.

immediate intraoperative difficulties with an arterial thrombus. This failure was attributed initially to recipient vessel spasm and donor vessel diameter. At the same operation, a salvage deep inferior epigastric artery perforator flap with pedicle length adequate to reach the retromandibular external carotid artery was difficult to infuse, requiring multiple arterial anastomoses and tissue plasminogen activator flush and heparin drip. The arterial anastomosis failed 12 hours later. Delayed reconstruction was performed using free tissue grafts and artificial dermal substitute. A postoperative hematologic workup revealed elevated plasminogen activator inhibitor-1 activity (79 percent; normal, 4 to 43 percent), protein S activity deficiency (57 percent; normal, 65 to 140 percent), elevated factor VIII activity (175 percent; normal, 50 to 150 percent), and elevated antiphosphatidyl immunoglobulin G and immunoglobulin M antibodies (G-phospholipid, 31 U/ml; M-phospholipid 26 U/ml; normal, <11 and <25 U/ml, respectively). Furthermore, gene testing by means of polymerase chain reaction techniques revealed that she was compound-heterozygous for the *C677T* and *A1298C* polymorphisms for the *MTHFR* gene mutation and was heterozygous for the *R506Q* polymorphism for the factor V Leiden gene.

Case 2

A 38-year-old white woman with right breast disseminated carcinoma in situ underwent bilateral mastectomy with immediate reconstruction by means of bilateral free transverse rectus abdominis musculocutaneous flap surgery. The patient had a 17-pack-year smoking history and a *BRCA1* mutation. Attempted bilateral muscle-sparing transverse rectus abdominis musculocutaneous flaps to the thoracodorsal arteries were attempted. Each flap anastomosis remained patent for approximately 30 minutes and then clotted. Attempted revision to the internal mammary artery vessels with papaverine administration and adventectomy were attempted, but the flap failed despite these efforts. A total of six anastomoses were attempted. Throughout the case, the anastomosed vessels appeared cloudy and flaccid. The flaps were discarded and the breast flaps were closed primarily.

A hematologic workup revealed that the patient carried a *PAI-1* gene mutation positive for one copy of the 4G allele, had protein S activity deficiency (54 percent; normal, 65 to 140 percent), and was a heterozygote for the factor V Leiden *R506Q* gene mutation.

Case 3

A 29-year-old white woman with left buccal sulcus carcinoma underwent wide local excision with radial forearm free flap reconstruction. Surgery was complicated by a return to the operating room for intermittent flow interruption and release of the tunnel for the vessels. The patient also developed a subsequent deep venous thrombosis from a peripherally inserted central catheter line.

Six months after a recurrence, a through-and-through defect on the cheek was reconstructed with a second radial forearm free flap to the superficial temporal vessels. Multiple arterial thromboses were encountered and the flap was finally well-vascularized until it went into spasm after an intraoperative dose of Neo-Synephrine (Bayer HealthCare, Leverkusen, Germany). Attempted salvage with a deep inferior epigastric artery perforator flap experienced significant inflow issues and was left lying on the cheek, as inset occluded flow (Fig. 1).

A postoperative hematologic workup revealed that the patient was homozygous positive for the *C677T* polymorphism for the *MTHFR* gene and had elevated levels of factor VIII activity (214 percent; normal, 50 to 150 percent). She was also found

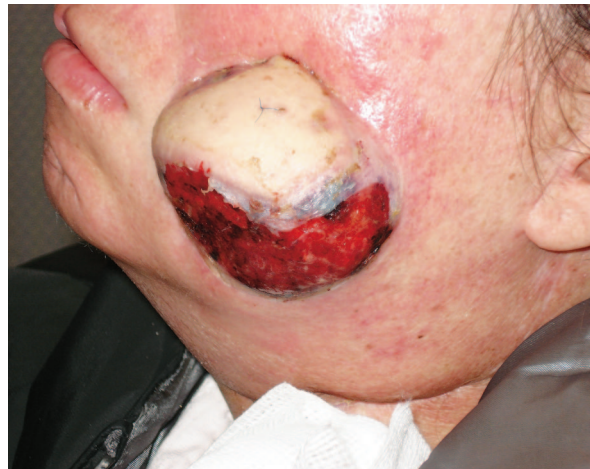

Fig. 1. A 29-year-old woman (the patient in case 3) with a recurrent left cheek carcinoma was left with a through-and-through defect of her cheek after tumor excision. After loss of the first free flap, a second free flap (deep inferior epigastric artery perforator) also experienced significant inflow problems and was left lying on the cheek as inset occluded flow.

to be hypothyroid, with a thyroid-stimulating factor level of 23 mIU/liter (normal, 0.23 to 5.6 mIU/liter) and a free thyroxine level of 0.51 ng/dl (normal, 0.58 to 1.64 ng/dl).

Case 4

A 42-year-old white woman with recurrent squamous cell cancer of the anterior floor of the mouth underwent composite resection including partial mandibulectomy. The patient had previously received irradiation to the site and had an extensive history of alcohol and tobacco use.

The oral defect was reconstructed using an immediate radial forearm free flap that was complicated by arterial clot that was cleared by thrombectomy in the same operative setting. Of note, the patient had had an arterial line placed previously in the donor extremity, and despite a negative Allen test preoperatively, the extremity donor site became ischemic and required a radial artery reconstruction using a vein graft in the same surgical setting.

The postoperative course was complicated by recurrent thrombosis of the free flap artery at the site of the previous arterial line, which resulted in loss of the radial forearm free flap (Fig. 2). The defect was then reconstructed in delayed fashion using an anterolateral thigh free flap, which developed postoperative necrosis of the distal half, although sufficient tissue survived to provide the needed soft-tissue coverage. In addition, the patient developed gangrene of one toe during her hospital stay, distal to the dorsalis pedis artery, which had been cannulated with an arterial catheter (Fig. 3).

Consultation with the hematology service and a hypercoagulable workup revealed that the patient was compound heterozygous for the *C677T/A1298C* polymorphisms for the *MTHFR* gene mutation. After the first failed free flap, the patient was fully heparinized (goal partial thromboplastin time, 60 to 80 seconds) until final flap survival was ascertained.

Intraoperative Findings

The intraoperative experience with these cases was similar. The flaps initially flashed up on the first anastomosis after

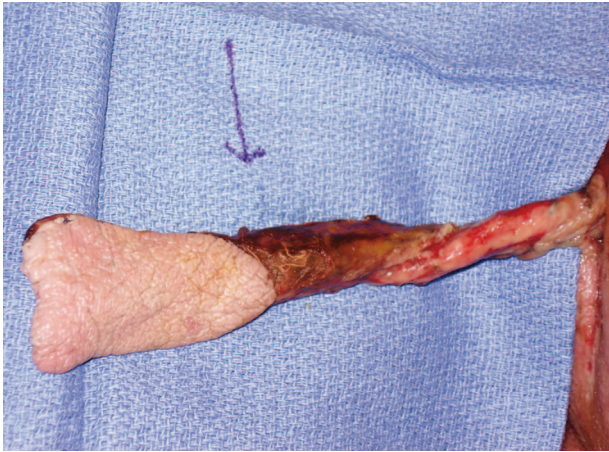


Fig. 2. A 42-year-old woman (the patient in case 4) underwent resection of a recurrent anterior floor-of-mouth carcinoma. The patient had recently had a radial arterial line, and subsequently a radial forearm free flap from the ipsilateral arm was used. The radial forearm free flap was lost following repeated occlusion at the site of the previous arterial line.

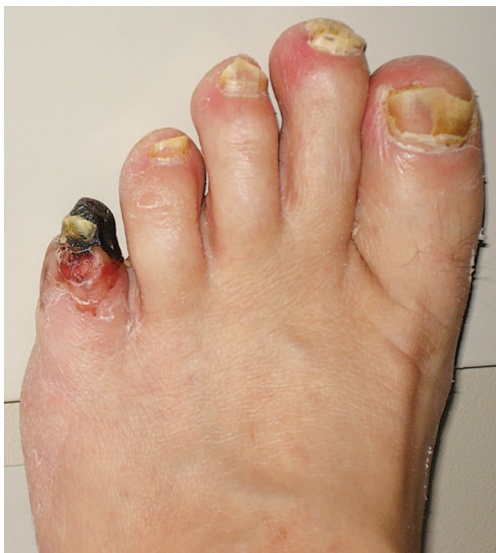

Fig. 3. Photograph of the same patient as in Figure 2 (case 4), in whom an arterial line was later placed into the dorsalis pedis artery. Within 2 days of placement of this arterial catheter, an ipsilateral toe became necrotic.

manipulation, with excellent hyperemic flow to the tissue. Within 5 to 20 minutes of flap perfusion, arterial flow ceased, with thrombus visualized at the anastomotic suture line or site of injury. Change in recipient vessel, donor flap, or surgical technique was not successful. Even use of a surgical anastomotic device to maintain patency by eliminating suture damage at the artery resulted in eventual thrombosis after 2 to 12 hours. The nature of the artery during surgical manipulation was flaccidity despite minimal trauma or cutting back the vessel to fresh tissue. Intraoperative findings that were common to these failed anastomoses were as follows:

1. The arterial anastomosis does not flash when the clamp is removed; it requires manipulation.
2. The arterial anastomosis goes down quickly (within 1 hour), before the rest of the procedure is completed.
3. The vessels, particularly the recipient flap vessels, are flaccid.
4. Topical agents such as papaverine and lidocaine do not appear to resolve the perfusion problem.
5. Heparin may make it worse.
6. Administration of intravascular thrombolytic agents (Acti-vase; Genentech, Inc., South San Francisco, Calif.) provides instant bright red bleeding from every cut surface, but thrombus quickly reaccumulates at the anastomotic site.

DISCUSSION

Microvascular free flap failure can be categorized into technical and patient-related factors. Of the latter group, previously diagnosed contributions have been stratified using advanced diagnostic paradigms, and patient selection criteria have been refined to optimize flap success rates.^{11–15} In contrast, our current series highlights patient factors that are not routinely or efficiently detected that appear to have led directly to failure in these four patients. All patients had arterial anastomosis failures that were essentially lost on the operating table, or were taken off the table as desperate salvage cases with little chance of success. These patients then required an alternative reconstructive option for defect closure.

In aggregate, these four patients had five total free flap losses, two partial flap losses, and one salvaged thrombus. These four patients represent 30 percent of the flap failures in 325 free flaps performed by the senior author (S.P.D.) in over a decade. In addition, they also had one deep vein thrombosis and two limb ischemic events.

Hypercoagulable events resulting from genetic and acquired causes are not rare in the general population. The most common genetic hypercoagulable states include mutations of coagulation factors V (factor V Leiden gene *R506Q* mutation) and II (prothrombin *G20210A* mutation); mutations of the methylene tetrahydrofolate reductase gene (*C677T* and *A1298C* polymorphisms), leading to hyperhomocysteinemia; and mutations of the plasminogen activator inhibitor-type 1 gene (4G/5G alleles), which modulates endogenous fibrinolytic activity. Other patients without a genetic predisposition can develop diseases, such as malignancy or autoimmune disorders (including antiphospholipid antibody syndrome), that produce a hypercoagulable state. Furthermore, certain medications can promote a procoagulopathic state. The hypercoagulable patient can be asymptomatic and undiagnosed, and in fact we probably operate on many patients whose hypercoagulable state is not known, suspected, or significant. A thorough fam-

ily medical history is probably the most valuable tool with which to reveal a genetic suspicion for hypercoagulability.

However, under certain circumstances, an undiagnosed hypercoagulopathy can become clinically relevant. In particular, the patients in our series were all undergoing microvascular free flap surgery following resection of head and neck squamous cell carcinoma or breast ductal carcinoma in situ. The combination of an underlying genetic predisposition to hypercoagulability, plus significant operative time (contributing an element of stasis), plus the presence of a squamous cell carcinoma or ductal carcinoma in situ (and their potential prothrombotic contribution), and the effects of inflammation on activation of coagulation, all coalesce into a clinical scenario where microvascular anastomosis becomes unfeasible. In our examples, these hypercoagulable events manifested themselves following many hours in the operating room, during which multiple microanastomoses were unsuccessfully attempted. Given the significant morbidity of extended operative time and microvascular reattempts, we suggest that certain intraoperative findings should raise the suspicion for a hypercoagulable state, and abandonment of microvascular repair be considered pending a thorough hematologic workup (Table 1). This scenario again emphasizes the value of a thorough preoperative family medical history.

Multiple reports have been presented in the literature of hypercoagulopathic events contributing to reconstructive complications. In particular, head and neck reconstruction cases have been noted to have free flap failure in patients with underlying coagulopathies.^{16,17} Similarly, undiagnosed hypercoagulopathy has been implicated in free flap failures in reconstruction of the breast,

extremities, and torso.^{6,9,10,18,19} Other hematologic disorders, and even medications that mediate hypercoagulability, have also been insinuated as the causes of microvascular anastomotic failure.^{20,21} Indeed, coagulopathy and hematologic disorders in general have been cited as factors in free flap outcomes but have been regarded as complex, difficult to assess preoperatively, and of variable significance.^{11,14,15,22}

Unfortunately, no routine, inexpensive, specific screening test predicts for the development of hypercoagulopathy-related perioperative complications. Screening for deep venous thrombosis risk and measurement of prothrombin time and partial thromboplastin time will identify some patients with possible coagulopathies; however, the majority of hypercoagulable patients are generally not detected preoperatively.²³ Once a hypercoagulable state is suspected—as in multiple microvessel anastomotic failures—a series of hematologic studies should be performed, often in consultation with the hematology service. The standard battery of tests include testing for antithrombin III deficiency, protein C and S deficiency, factor V Leiden, and homocysteine levels (Table 2). In addition, several endocrine conditions could aggravate the hypercoagulable state, and therefore thyroid status (thyroid-stimulating hormone, free thyroxine) and adrenal function (free AM cortisone level, cortisone-stimulating test) should also be considered. Research tools that measure endogenous thrombin generation or global clot formation (such as those that use the thromboelastogram or its variants) might be useful in future development of effective screening tests.

Management of these patients changes once a diagnosis of a hypercoagulable state is established. First, the operative defect should be temporized using dressing changes until more definitive reconstruction can be safely performed. Second, immediate perioperative anticoagulation needs to be initiated, as the hypercoagulable state places the

Table 1. Clinical Findings Suggestive of a Hypercoagulable State during Microsurgery

The arterial anastomosis does not flash when the clamp is removed; it requires manipulation
The arterial anastomosis occludes promptly (within 1 hr) before the rest of the case is completed
The vessels, particularly the recipient flap vessels, are flaccid
Topical agents such as papaverine and lidocaine do not improve flow
Unfractionated heparin appears to aggravate the hypercoagulability
Administration of intravascular thrombolytic agents (tissue plasminogen activator) provides instant bright red bleeding from every cut surface, but thrombus quickly reaccumulates at the anastomotic site

Table 2. Tests for Genetically Determined Hypercoagulable States

Factor V Leiden gene mutation
Prothrombin <i>A20210G</i> gene mutation
<i>MTHFR</i> gene mutation
<i>PAI-1</i> gene mutation
Protein C and S activity deficiency
Antithrombin III deficiency
Lupus anticoagulant
Plasma homocysteine level
Anticardiolipin antibody
Antiphospholipid antibody
β 2-glycoprotein antibody

patient at high risk for postoperative venous thromboembolism/deep venous thrombosis. Third, plans for long-term anticoagulation, if any, need to be coordinated with the hematology service. Some hypercoagulable patients (those with lupus or malignancy) might need protracted anticoagulation, whereas other patients simply require counseling on anticoagulation strategies during future scenarios associated with high risk of venous thromboembolism, such as operations, long plane flights, pregnancy, and other conditions that might unmask their predisposition to hypercoagulability.

The plastic surgical literature has only several case reports of microvascular free flaps complicated by hypercoagulable states; yet if these conditions are present in up to 10 percent of the population, why are reports of these complications so scarce? The main reason is that microsurgical reconstruction, as in our institution, is becoming significantly more aggressive. The patients in this series all had locally advanced squamous cell carcinoma of the head and neck or breast adenocarcinoma. Most of the patients presented as recurrences, with preoperative irradiation to this site. All of the patients had significant tobacco and/or alcohol comorbidity, with nutritional deficiency. Every patient had surgical extirpation of the tumor in the same surgical setting as the initial microsurgical reconstruction, necessitating operative times in excess of 10 hours and intraoperative tumor manipulation. Finally, these patients also had at least one genetic hypercoagulable mutation; some patients had up to three separate mutations. Hypercoagulable events are often a clinical reflection of synergistic genetic abnormality with environmental conditions, and this synergy is exemplified in this patient population. We suspect that as the indications for free flap reconstruction continue to expand, this scenario will become increasingly recognized.

More than other malignancies, squamous cell carcinoma appears to have particular prothrombotic effects. It is noteworthy that three of the patients in this series had a locally advanced (often recurrent) squamous cell carcinoma, with tumor manipulation and extirpation immediately preceding the initial microvascular attempt. The prothrombotic, coagulopathic effect of squamous cell carcinoma, and the potential for aggravating the condition with surgical manipulation, could have had an effect on the coagulopathies of the patients in this case series.^{23–29}

CONCLUSIONS

Patients with multiple coagulopathic abnormalities that have free flap failure should probably have a hematology consultation that includes a thorough coagulopathic workup. The hematologist, ideally with the plastic surgeon, should then counsel the patient as to his or her condition and the associated risks. Importantly, the patient should be advised on the use of prophylaxis for deep venous thrombosis and pulmonary embolus during future surgical procedures, prolonged immobilization, long car rides, and plane flights.

Steven P. Davison, D.D.S., M.D.

Da Vinci Plastic Surgery
3301 New Mexico Avenue, Suite 236
Washington, D.C. 20016
davisonplastic@yahoo.com

REFERENCES

1. Godina M. Preferential use of end-to-side arterial anastomoses in free flap transfers. *Plast Reconstr Surg*. 1979;64:673–682.
2. Fogdestam I. Experiences with free flap surgery. *Ann Chir Gynaecol*. 1982;71:38–43.
3. Bui DT, Cordeiro PG, Hu QY, Disa JJ, Pusic A, Mehrara BJ. Free flap reexploration: Indications, treatment, and outcomes in 1193 free flaps. *Plast Reconstr Surg*. 2007;119:2092–2100.
4. Okazaki M, Asato H, Takushima A, et al. Analysis of salvage treatments following the failure of free flap transfer caused by vascular thrombosis in reconstruction for head and neck cancer. *Plast Reconstr Surg*. 2007;119:1223–1232.
5. Chen KT, Mardini S, Chuang DC, et al. Timing of presentation of the first signs of vascular compromise dictates the salvage outcomes of free flap transfers. *Plast Reconstr Surg*. 2007;120:187–195.
6. Tremblay DM, Harris PG, Gagnon AR, Cordoba C, Brutus JP, Nikolis A. Heparin-induced thrombocytopenia syndrome as a cause of flap failure: A report of two cases. *J Plast Reconstr Aesthet Surg*. 2008;61:78–83.
7. Wax MK, Rosenthal E. Etiology of late free flap failures occurring after hospital discharge. *Laryngoscope* 2007;117:1961–1963.
8. Bozikov K, Arnez ZM. Factors predicting free flap complications in head and neck reconstruction. *J Plast Reconstr Aesthet Surg*. 2006;59:737–742.
9. Baumeister S, Follmar K, Zenn M, Erdmann D, Levin LS. Strategy for reoperative free flaps after failure of a first flap. *Plast Reconstr Surg*. 2008;122:962–971.
10. Vekris MD, Ovrenovits M, Dova L, et al. Free functional muscle transfer failure and thrombophilic gene mutations as a potential risk factor: A case report. *Microsurgery* 2007;27:88–90.
11. Serletti JM, Higgins JP, Moran S, Orlando GS. Factors affecting outcome in free-tissue transfer in the elderly. *Plast Reconstr Surg*. 2000;106:66–70.
12. Nahabedian MY, Momen B, Manson PN. Factors associated with anastomotic failure after microvascular reconstruction of the breast. *Plast Reconstr Surg*. 2004;114:74–82.
13. Nahabedian MY, Singh N, Deune EG, Silverman R, Tufaro AP. Recipient vessel analysis for microvascular reconstruction of the head and neck. *Ann Plast Surg*. 2004;52:148–155; discussion 156–157.

14. Chen HC, Coskunfirat OK, Ozkan O, et al. Guidelines for the optimization of microsurgery in atherosclerotic patients. *Microsurgery* 2006;26:356–362.
15. Blackwell KE, Brown MT, Gonzalez D. Overcoming the learning curve in microvascular head and neck reconstruction. *Arch Otolaryngol Head Neck Surg*. 1997;123:1332–1335.
16. Ayala C, Blackwell KE. Protein C deficiency in microvascular head and neck reconstruction. *Laryngoscope* 1999;109:259–265.
17. Di Spilimbergo SS, Rampazzo A, Squaquara R, Penzo M, Padula E. Hypercoagulability due to homocystinuria in a case of head and neck reconstruction resolved with systemic therapy. *Plast Reconstr Surg*. 2008;121:1508–1509; discussion 1509–1510.
18. Olsson E, Hoijer P. Activated protein C resistance due to factor V Leiden, elevated coagulation factor VIII, and postoperative deep vein thrombosis in late breast reconstruction with a free TRAM flap: A report of two cases. *Br J Plast Surg*. 2005;58:720–723.
19. Labow BI, Green AK, Upton J. Homocystinuria: An unrecognized cause of microvascular failure. *Plast Reconstr Surg*. 2007;120:6e–12e.
20. Al-Sukhun J, Koivusalo A, Tornwall J, Lindqvist C. COX-2 inhibitors and early failure of free vascular flaps. *N Engl J Med*. 2006;355:528–529.
21. Choe EI, Kasabian AK, Kolker AR, et al. Thrombocytosis after major lower extremity trauma: Mechanism and possible role in free flap failure. *Ann Plast Surg*. 1996;36:489–494.
22. Hoijer P, Olsson E. Elevated coagulation factor VIII, postoperative thrombosis and flap failure in late breast reconstruction with a free TRAM flap: A case report. *J Plast Reconstr Aesthet Surg*. 2006;59:102–104.
23. Davison SP, Venturi ML, Attinger CE, Baker SB, Spear SL. Prevention of venous thromboembolism in the plastic surgery patient. *Plast Reconstr Surg*. 2004;114:43E–51E.
24. Avances C, Jacot W, Senesse P, Culine S. Prompt resolution of acute disseminated intravascular coagulation with docetaxel and cisplatin in hormone refractory prostate cancer. *J Urol*. 2002;168:1496.
25. Navarro M, Ruiz I, Martin G, Cruz JJ. Patient with disseminated intravascular coagulation as the first manifestation of adenocarcinoma of the prostate: Risks of prostatic biopsy. *Prostate Cancer Prostatic Dis*. 2006;9:190–191.
26. Ng HJ, Crowther MA. Malignancy-associated venous thrombosis with concurrent warfarin-induced skin necrosis, venous limb gangrene and thrombotic microangiopathy. *Thromb Haemost*. 2006;95:1038–1039.
27. Koenig MA, Maleszewski J, Winters B. Multiple hemorrhagic strokes from DIC associated with occult large cell carcinoma. *Neurocrit Care* 2006;5:210–212.
28. Zurada JM, Ward KM, Grossman ME. Henoch-Schönlein purpura associated with malignancy in adults. *J Am Acad Dermatol*. 2006;55:S65–S70.
29. Hauser I, Lechner K. Solid tumors and factor VIII antibodies. *Thromb Haemost*. 1999;82:1005–1007.

Contacting the Editorial Office

To reach the Editorial Office, please use the following contact information:

Plastic and Reconstructive Surgery

Rod J. Rohrich, M.D., Editor-in-Chief

St. Paul's Hospital

5909 Harry Hines Boulevard

Room HD01.544

Dallas, Texas 75235-8820

Tel: 214-645-7790

Fax: 214-645-7791

E-mail: PRS@plasticsurgery.org