

Aesthetic Subunits of the Breast

Scott L. Spear, M.D., and Steven P. Davison, D.D.S., M.D.

Washington, D.C.

Surgery for breast cancer has traditionally addressed the breast as if it were a geometric circle with associated quadrants. Cosmetic reconstruction should not follow geometric patterns but should emphasize perceived contour and normal clothing lines. Similar to nasal reconstruction, a subunit principle in breast reconstruction planning may significantly improve the appearance of the result. To better identify the most aesthetic subunits for breast reconstruction, 10 years of autogenous reconstruction in 264 patients was reviewed. Various patterns of breast subunits were identified. The more favorable subunits of the breast in terms of postoperative appearance and camouflage of scars included the nipple, areola, and expanded areola subunits. For larger skin defects, the best subunits were the inferolateral, lower half, and a total breast subunits. Dividing the breast into reconstructive subunits that are to be replaced as a whole rather than as a patch gives superior results. Photographed examples of aesthetic subunits illustrate the placement of scars along natural lines that maximize the advantages of camouflage afforded by clothing. (*Plast. Reconstr. Surg.* 112: 440, 2003.)

One goal of breast reconstruction is to restore the breast as normally and attractively as possible while minimizing visible scars. Augmentation mammoplasty techniques have always instinctively emphasized hiding scars in natural lines, such as the inframammary fold, the edge of the areola, and the axilla. In the breast cancer literature, the breast has been described as a geometric circle with quadrants which, although easy to comprehend, do not represent the breast mass, which is teardrop shaped, and do not consider aesthetic lines of demarcation.

Burget and Menick¹ are credited with advancing nasal reconstruction by describing the nose in reconstructive subunits. Burget and Menick's subunit principle was also an extension of Millard's use of the Abbé flap to correct the previously unsuccessful repair of a unilat-

eral cleft lip.² Instead of using the Abbé flap in the lateral defect, Millard replaced the entire philtrum subunit, releasing the lip structure and maximizing natural boundaries. Burget and Menick's subunit approach to nasal reconstruction dictates that the complete replacement of units that places the border of flaps in shadowed valleys and on the lighter ridges of the nasal surface improves results. Breast reconstruction obviously differs from nasal reconstruction because the breast lacks the shadowed valleys and light ridges that are present on the nose, but the concept of aesthetic units to hide scars might also apply. However, unlike the lip or the nose, the majority of the breast is often covered in clothing, adding a new dimension for camouflage.

An approach to breast reconstruction that emphasizes the perceived subunits of the breast might help the surgeon in choosing more cosmetically attractive reconstructive options. For example, incision lines that extend outside the natural lines of the breast that are uncovered by clothing can be unsightly. The short transverse incision above the opposite breast that is so often used for placement of the chemotherapy infusion catheter is often the most unattractive reminder of the entire reconstruction process. It is prominent, fails to follow any light shadows or creases, and is virtually impossible to camouflage. Restifo³ refers to the concept of aesthetic subunits in delayed transverse rectus abdominis musculocutaneous (TRAM) flap reconstruction. In cases in which the lower mastectomy flap was compromised, he prefers to replace all the skin down to the inframammary fold as a subunit using the TRAM skin island.³ Coutinho et al.⁴ studied breast scar aesthetics and found that patients

From the Division of Plastic Surgery, Georgetown University Medical Center. Received for publication June 7, 2002; revised October 17, 2002.

DOI: 10.1097/01.PRS.0000070486.35968.38

preferred single horizontal or oblique lines that avoided the superomedial quadrant. In the subunit concept, a better aesthetic result may be achieved by creating a larger defect by sacrificing normal breast skin to hide transitions at subunit margins.⁵ The purpose of this investigation was to determine whether we could better define the subunits of the breast by reviewing our flap breast reconstructions and observing which flap and scar patterns were the most cosmetically successful and which were aesthetically disappointing.

PATIENTS AND METHODS

A large series of autogenous breast reconstructions completed over a 10-year period were retrospectively reviewed. A total of 264 reconstructions were evaluated. This included 233 TRAM flaps and 31 latissimus dorsi reconstructions. The patients' preoperative and postoperative photographs were evaluated for the following elements: natural contours and landmarks, including the inframammary fold, the periareola, and the anterior axillary line; patterns of surgical incision routinely used by the oncologic surgeon; and tan lines or demarcation lines on the skin of the breast present preoperatively or postoperatively. Results were placed into one of two groups. In the first group, subunits of the flaps used in the breast reconstruction were considered favorable; the second group consisted of flaps for which the

design and pattern were cosmetically unfavorable.

RESULTS

We found two distinct groups of reconstructions: flap reconstructions with good appearance within aesthetic subunits, and flap reconstructions with a patch-like appearance where the flap design did not follow any particular aesthetic subunit. These subunits were then subdivided according to boundary type.

The desirable aesthetic subunits of the breast are those which are outlined by tissue, color, or texture changes. Examples of these transitions are (1) breast skin to areola, (2) areola to nipple, (3) breast skin to chest skin at the inframammary fold, (4) anterior axillary line, and (5) breast to sternal skin (Fig. 1). Aesthetic subunits of the breast delineated by these transitions are outlined in Figure 2.

The best aesthetic units are expanded concentric circles around the nipple, particularly when a larger circle of skin, from 3 to 4 cm, is used to replace the areola in a skin-sparing mastectomy (Fig. 3). The use of the latissimus or TRAM flap to reconstruct the areola in a skin-sparing mastectomy is perhaps the ideal aesthetic unit in breast reconstruction. If more skin is excised than the areola, a larger 5-cm to 6-cm concentric skin subunit is still visually acceptable as an expanded areolar subunit. The eye is accustomed to viewing a circular

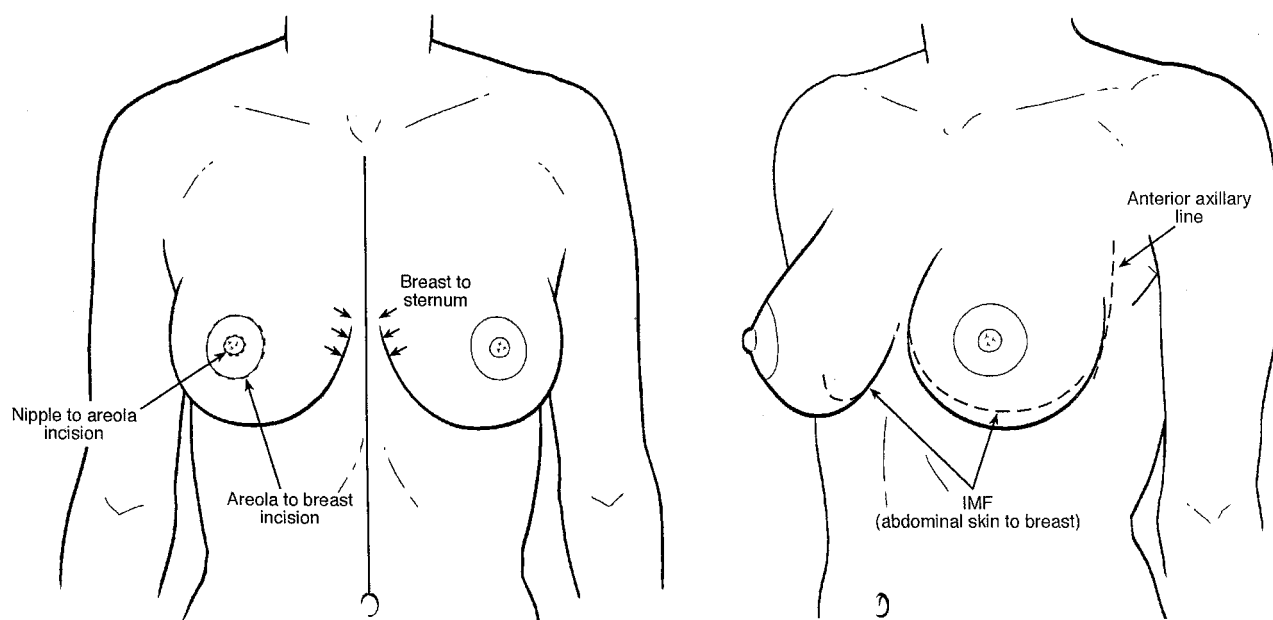


FIG. 1. The limited transition lines around the breast include the nipple, areola, inframammary fold (IMF), and anterior axillary line, which can camouflage breast reconstruction.

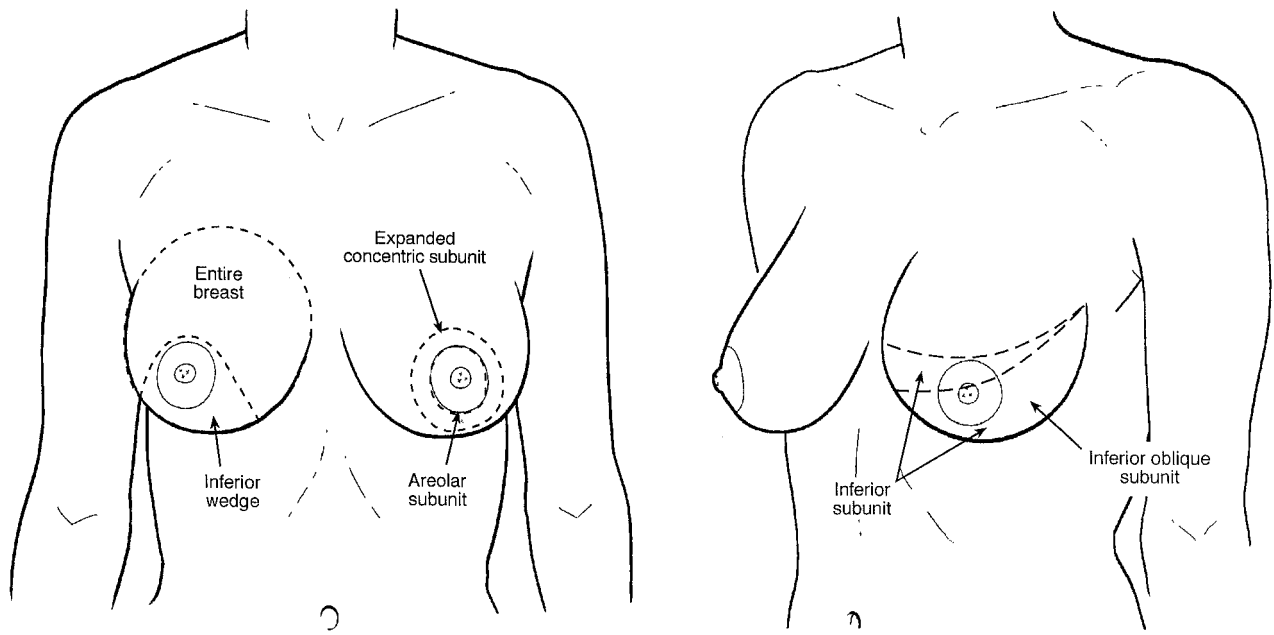


FIG. 2. Drawing of aesthetic subunits on the breast that represent favorable use of the transition lines. These include the periareolar units, the inferior lateral subunits, and the entire breast.

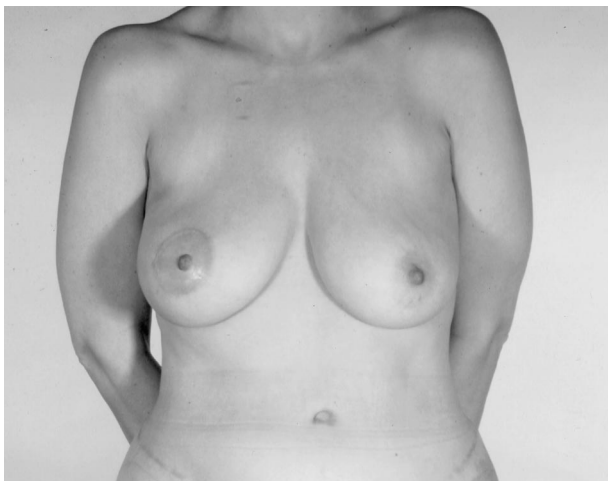


FIG. 3. The areolar margin is the ideal transition for this subunit in a subcutaneous mastectomy. The right breast is reconstructed with a unilateral pedicle TRAM flap.

areola, and a large concentric circular subunit is also acceptable (Fig. 4).

Another attractive subunit uses the horizontal nipple plane as the upper limit. The first of these aesthetic subunits is the lower outer crescent that corresponds to the skin that can be replaced by the latissimus flap (Fig. 5). An expansion of this is the lower lateral half of the breast. This is the skin from the transverse or oblique mastectomy incision extending down toward the inframammary fold. It replaces the skin with an entire aesthetic subunit that can be from either a pedicle TRAM flap, a free

TRAM flap, or a large latissimus flap. The lateral margins of this subunit follow the shadow created by the transition of the breast to the back and flank at the anterior axillary line (Fig. 2). Removal of a portion of normal inferior breast skin down to the inframammary fold may be necessary to maximize aesthetics. The final line of closure lies at and is hidden in the inframammary fold (Fig. 6).

The inferolateral crescent of the breast, from the 4 o'clock to 9 o'clock position on the right and the 3 o'clock to 8 o'clock position on the left, is also an acceptable aesthetic subunit shaped like an inferiorly based pie slice. It corresponds to tan lines or clothing seen with certain undergarments or bathing suit patterns; although it is not strictly anatomic, it is perceived as a natural contour. It is not unusual to the eye and remains hidden in a shadow of the breast (Fig. 7).

The largest subunit of the breast is the subunit of the entire breast. This subunit is outlined by the medial aspect of the breast and the inframammary fold, and laterally by the anterior axillary line. It is possible to reconstruct this subunit with TRAM flaps, particularly free TRAM flaps, when using a generous skin harvest. The drape of this flap can use a pattern described by Cohen to maximize projection and coning of the breast (Fig. 8). An extension of the subunit

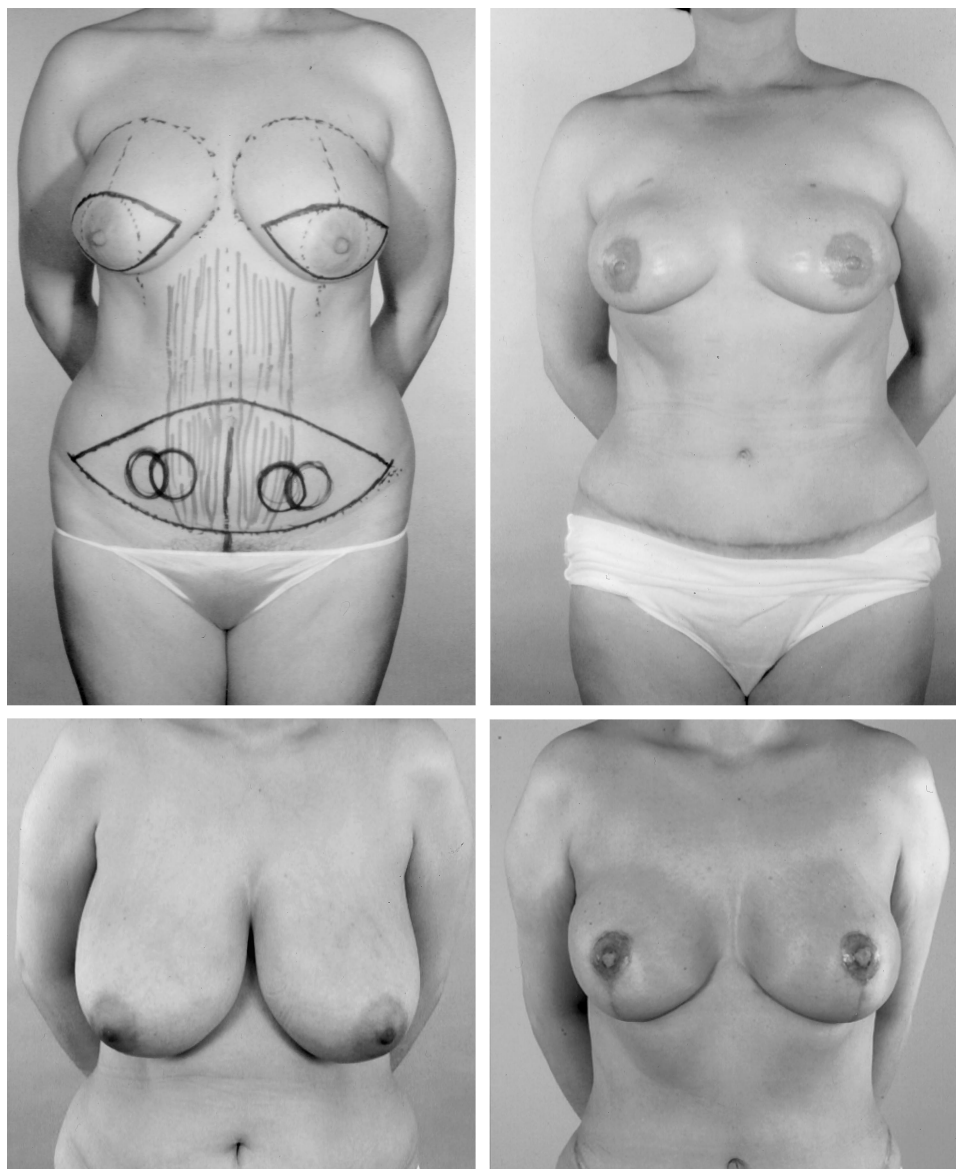


FIG. 4. Examples of larger periareolar subunits replaced with bilateral pedicle TRAM flap patterns. One example uses mastopexy techniques to reduce the skin envelope.

to the sternal skin can improve the aesthetic subunit (Fig. 8, *right*).

The most noticeable unaesthetic unit of the breast is a random patch. Examples of the random patch are drawn in a line diagram (Fig. 9). The difference in color and texture of the patch accentuates the stuck-on appearance of this flap for reconstruction (Fig. 10). Fortunately, this postage stamp-like reconstruction is not typically compounded by the pincushioning seen in nasal reconstruction. Resection of the surrounding area of the patch up to breast boundaries to convert it to an aesthetic subunit is preferable. Another unaesthetic pattern is the use of the skin of the latissimus flap to

replace the mastectomy scar, creating a central patch with inferior and superior transverse scars (Fig. 11).

Other less aesthetic units are the upper inner quadrant, the medial half, and the inferomedial quadrant. The random patch, when located superomedially, is the least aesthetic subunit. These subunits place the skin island where the cleavage and transition from breast to tightly adherent sternal skin make camouflage difficult (Fig. 12).

DISCUSSION

When Burget and Menick¹ describe the aesthetic subunits of the nose, they emphasize

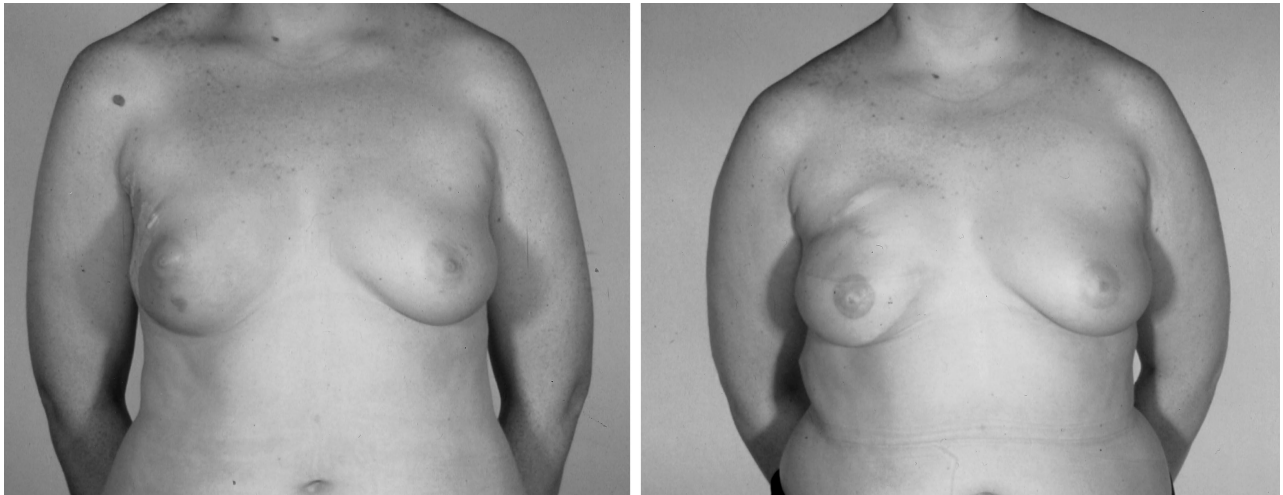


FIG. 5. An aesthetic subunit is the inferior pole of the breast and lateral inferior cup with the watermark at the oblique nipple plane. Note previous mastectomy scar along the upper breast border.

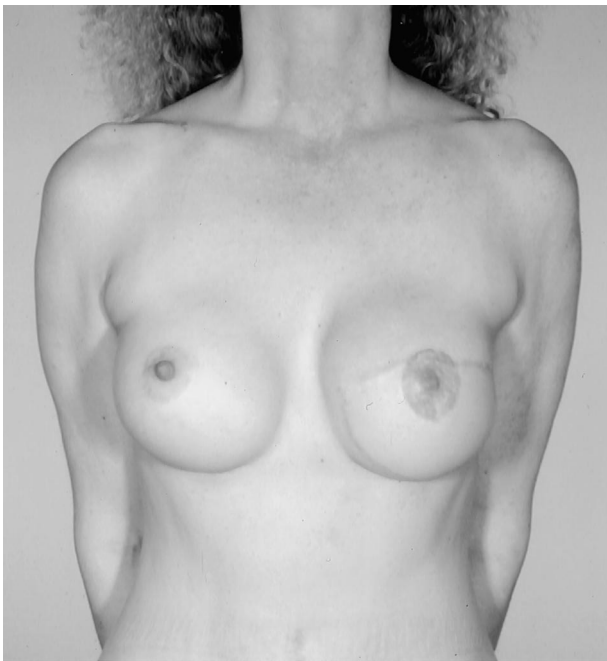


FIG. 6. An aesthetic replacement of the lower half of the breast. The flap extends to the inframammary fold, hiding the transition.

hiding scars in ridges and valleys between topographic units. The breast differs from the nose because the only natural transition is from the areola to breast skin and from the breast skin to the chest at the inframammary fold. Sacrifice of the breast skin superior to this inframammary fold to hide a transition mirrors the subunit excision in nasal reconstruction. Clothing and tan lines constitute the other transitions to assist in breast reconstruction camouflage. Consistent problems with reconstruction are the patch-like appearance of

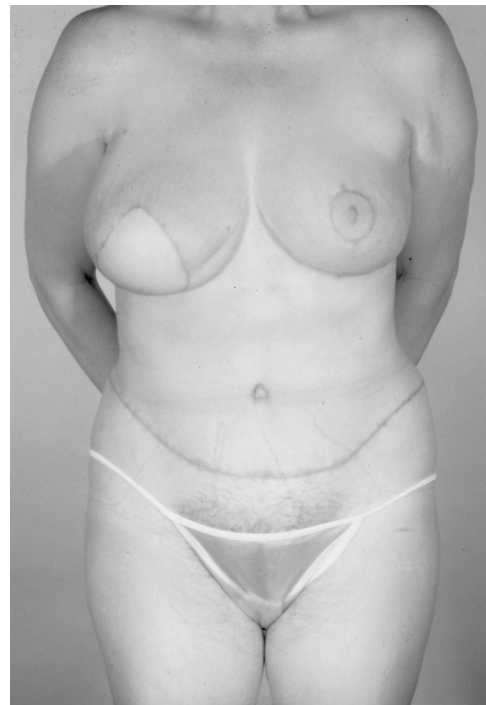

FIG. 7. An inferiorly based pie slice is well accepted and mimics the triangle of a bikini top.

poorly placed skin or scars. Hidalgo,⁵ Restifo,³ Gabka et al.,⁶ and Nahai⁷ have all condemned this type of appearance. The development of the circumareolar mastopexy, with immediate reconstruction using either TRAM or latissimus flap reconstruction as described by Bensimon and Bergmeyer,⁸ has raised the standard for autogenous reconstruction. The first group of aesthetic subunits, the nipple-areola and extended periareolar units, follow this philosophy.⁹ The concentric circle located on top of

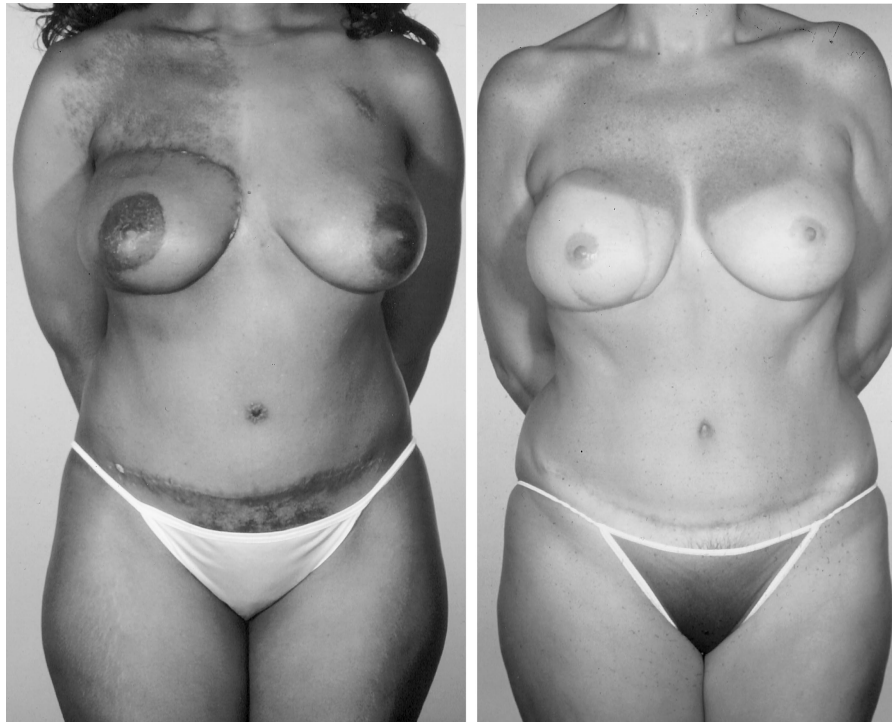


FIG. 8. Examples of TRAM flap replacement of an entire breast subunit. The extension to the sternal skin junction hides the reconstruction in the dark-skin patient (*left*). An extension to the sternal skin in the light-skin patient would have improved the aesthetic subunit (*right*).

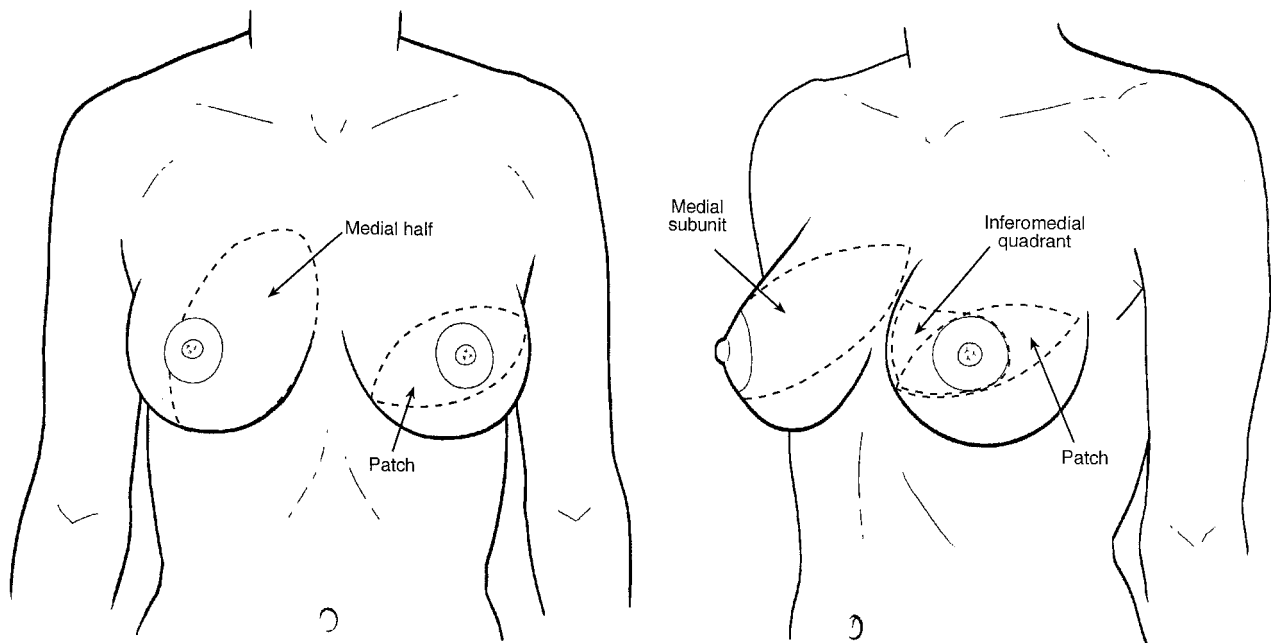


FIG. 9. Drawings of less aesthetic units of the reconstructed breast include patch reconstruction and impingement on the medial breast.

the breast mound is visually acceptable, replicating the nipple-areola complex. When small, between 4 and 5 cm, the skin island can be completely incorporated into the new areola

and pigmented with camouflaging tattoos (Figs. 3 and 4).

Coutinho et al.⁴ made an excellent attempt to identify aesthetic implications of scar posi-

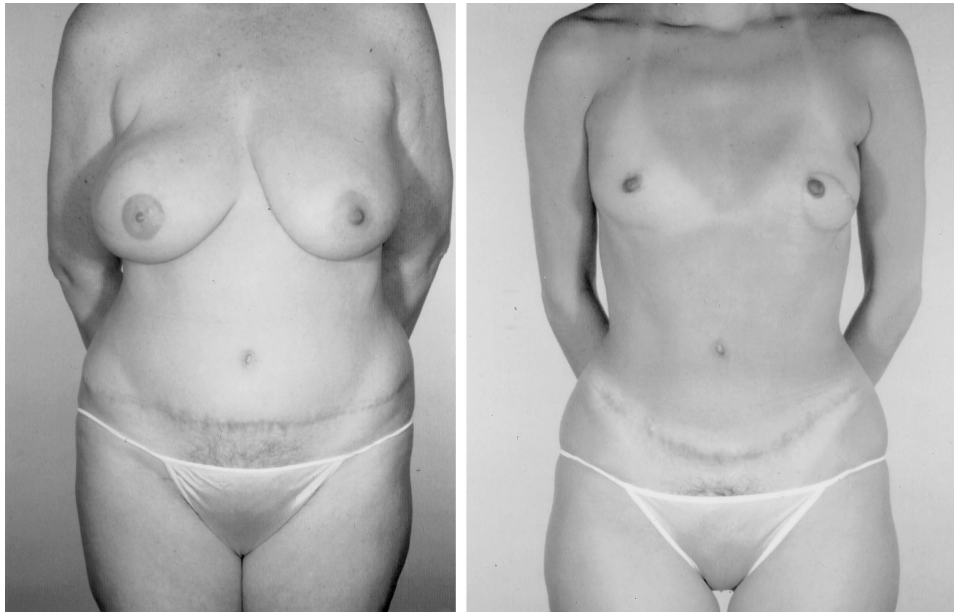


FIG. 10. The random patch is a less aesthetic subunit. Two obvious examples are shown here.

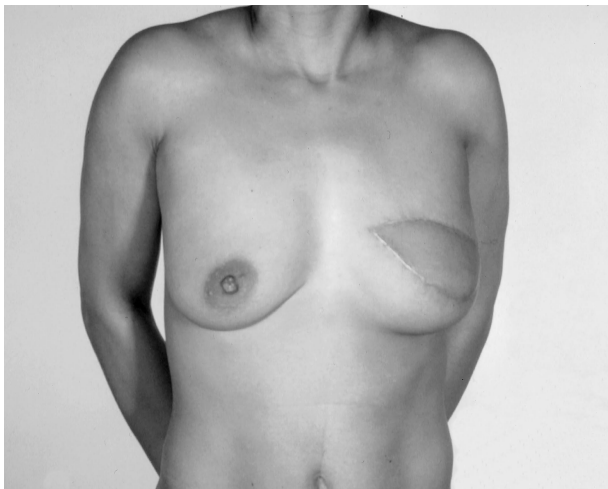


FIG. 11. Unaesthetic use of the latissimus flap to replace the mastectomy scar creates a central patch on the breast.

tion in breast reconstruction. However, their study is handicapped because, to simulate scars, lines were drawn on normal breasts with intact areolar complexes. These were then used as a scar comparison. This study is artificial because most mastectomies involve the areola. The maintenance of the areola limits the extrapolation of these two studies to the periareolar subunit. They found that subjects preferred a single scar, running in an oblique direction from the high lateral to low medial quadrant. This type of scar would be seen in the inferolateral crescent subunit or inferior subunit reconstruction where the other incision line is hidden in the inframammary fold.

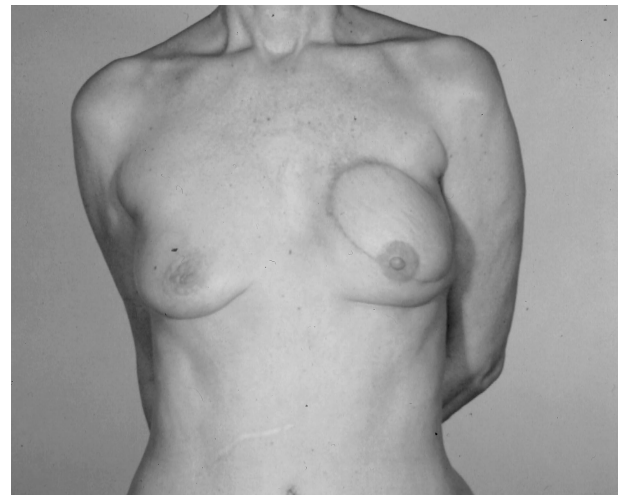


FIG. 12. The least aesthetic subunit with supermedial encroachment. This is difficult to camouflage with clothing. This example uses no subunit principles.

The worst patterns for scar or flap design in their study were oblique patterns that encroached on the medial upper quadrant, a finding with which we agree.

Restifo³ has described the TRAM flap as an aesthetic unit when it is used to replace skin down to the inframammary fold. This avoids a patch-like appearance and uses the inframammary fold as a transition. Carlson et al.¹⁰ have emphasized leaving the inframammary fold itself, which is difficult to replicate. Extrapolating Restifo's³ technique from the TRAM to the latissimus skin paddle identifies the inferolateral crescent as an aesthetic subunit. The latis-

simus flap is best used in the skin-sparing mastectomy to immediately replace the areola or to replace the inferolateral quadrant in delayed reconstructions. This skin paddle simulates the appearance of a demi-bra or brief bikini top. The transition from flap to native skin can replicate where sun-exposed and non-sun-exposed skin meet. In contrast, the use of the latissimus along the length of the mastectomy scar provides a nonaesthetic, patch repair (Fig. 11). The use of a free TRAM flap to reconstruct the entire breast as described by Cohen¹¹ is a favorable pattern. It replaces the breast as a subunit surrounded by transition lines of the inframammary fold, the anterior axillary line, and the breast to sternal skin (Fig. 8, *left*).

CONCLUSIONS

The standards for breast reconstruction continue to improve. Recreating a breast mound is no longer sufficient. Patients and surgeons alike expect reasonable symmetry, natural-appearing reconstructed nipples, and attractive breasts. To achieve these goals, the camouflage or avoidance of scars has become increasingly important. The aesthetic lines for scar placement in breast reconstruction should incorporate the inframammary fold, the areola, or the anterior axillary line as much as possible. The best aesthetic subunits of the breast include the periareolar subunit, the inferior half of the breast, the inferolateral crescent, and the whole breast.

The less aesthetic or unattractive subunits include a superomedial or medial quadrant and the central random patch. In planning breast reconstruction, sometimes *less* skin excision gives a more attractive result; however, in other situations, sometimes *more* skin excisions create less obtrusive scars or other deformities.

Scott L. Spear, M.D.
Division of Plastic Surgery
Georgetown University Hospital
3800 Reservoir Road, N.W.
Washington, D.C. 20007
spears@gunet.georgetown.edu

REFERENCES

1. Burget, G. G., and Menick, F. J. Subunit principle in nasal reconstruction. *Plast. Reconstr. Surg.* 76: 239, 1985.
2. Millard, D. R. Shaping and positioning the lip-switch flap in unilateral clefts. In *Cleft Craft*. Boston: Little, Brown, 1976. Pp. 593–628.
3. Restifo, R. J. The aesthetic subunit principal in late TRAM flap breast reconstruction. *Ann. Plast. Surg.* 43: 235, 1999.
4. Coutinho, M., Southern, S., Ramakrishnan, V., Watt, D., Fourie, L., and Sharpe, D. T. The aesthetic implications of scar position in breast reconstruction. *Br. J. Plast. Surg.* 54: 326, 2001.
5. Hidalgo, D. A. Aesthetic refinement of breast reconstruction: Complete skin-sparing mastectomy with autogenous tissue transfer. *Plast. Reconstr. Surg.* 102: 63, 1998.
6. Gabka, C. J., Maiwald, G., and Bohmert, H. Immediate breast reconstruction for breast carcinoma using the periareolar approach. *Plast. Reconstr. Surg.* 104: 1128, 1998.
7. Nahai, F. Aesthetic refinement of breast reconstruction: Complete skin-sparing mastectomy with autogenous tissue transfer. *Plast. Reconstr. Surg.* 102: 70, 1998.
8. Bensimon, R. H., and Bergmeyer, J. M. Improved aesthetics in breast reconstruction, modified mastectomy incision and immediate autogenous tissue reconstruction. *Ann. Plast. Surg.* 34: 229, 1995.
9. Grotting, J. Personal communication, 2002.
10. Carlson, G. W., Grossl, N., Lewis, M. M., Temple, J. R., and Styblo, T. M. Preservation of the inframammary fold: What are we leaving behind? *Plast. Reconstr. Surg.* 98: 447, 1996.
11. Cohen, L. B. One-stage reconstruction of the breast using autologous tissue with immediate nipple reconstruction. In S. L. Spear, J. W. Little, M. E. Lippman, and W. C. Wood (Eds.), *Surgery of the Breast: Principles and Art*. Philadelphia: Lippincott-Raven, 1998. Pp. 491–510.