

Aesthetic Surgery Journal

<http://aes.sagepub.com/>

Efficacy of Intralesional 5-Fluorouracil and Triamcinolone in the Treatment of Keloids

Steven P. Davison, Joseph H. Dayan, Mark W. Clemens, Smitha Sonni, Antai Wang and Amy Crane

Aesthetic Surgery Journal 2009 29: 40

DOI: 10.1016/j.asj.2008.11.006

The online version of this article can be found at:

<http://aes.sagepub.com/content/29/1/40>

Published by:



<http://www.sagepublications.com>

On behalf of:



[American Society for Aesthetic Plastic Surgery](#)

Additional services and information for *Aesthetic Surgery Journal* can be found at:

Email Alerts: <http://aes.sagepub.com/cgi/alerts>

Subscriptions: <http://aes.sagepub.com/subscriptions>

Reprints: <http://www.sagepub.com/journalsReprints.nav>

Permissions: <http://www.sagepub.com/journalsPermissions.nav>

Efficacy of Intralesional 5-Fluorouracil and Triamcinolone in the Treatment of Keloids

Steven P. Davison, DDS, MD; Joseph H. Dayan, MD; Mark W. Clemens, MD; Smitha Sonni, MD; Antai Wang, PhD; and Amy Crane, MD

BACKGROUND: Keloids are a common problem with significant recurrence rates despite intralesional steroid treatment and multimodal therapy.

OBJECTIVE: The purpose of this study was to evaluate the efficacy of using a 5-fluorouracil (5-FU)/steroid mixture to treat keloids over the past 7 years, comparing the results with use of steroid treatment alone.

METHODS: Patient charts from 1999 to 2006 were reviewed. Patients were stratified into 3 groups: (1) 5-FU/steroid without excision; (2) 5-FU/steroid with excision; and (3) steroid treatment with excision. The percentage of lesion size reduction and symptoms were evaluated.

RESULTS: A total of 102 keloids were identified in a retrospective review. Patients who underwent the 5-FU/steroid combination with excision had a 92% average reduction in lesion size compared with 73% in the group of patients who did not receive 5-FU. Patients who received 5-FU/steroid without excision had an average lesion size reduction of 81%. Differences in complication rates were not statistically significant.

CONCLUSIONS: Combination 5-FU/triamcinolone is superior to intralesional steroid therapy in the treatment of keloids. (*Aesthetic Surg J* 2009;29:40–46.)

The pathogenesis of keloids remains controversial. Although there is a lack of consensus about an ideal standard therapy, there is a significant need for an effective treatment protocol because keloids are common and tend to recur.¹⁻¹² The incidence of keloids is reported to be 4.5% to 16% in darker-skinned individuals.^{3,4} Traditionally, intralesional triamcinolone has been the mainstay of keloid treatment, in conjunction with reexcision and adjuvant therapies such as radiation and compression. Here, we study the efficacy of intralesional injection of 5-fluorouracil (5-FU) combined with triamcinolone in treating keloids.

Conventional therapy for keloids may yield a frustrating number of recurrences. Intralesional steroid injection combined with excision has resulted in efficacy rates ranging from 58% to 93% in several studies.^{2,5,6,8} Despite the vast array of keloid therapies, there are still a significant number of treatment failures and a substantial inconsistency in the reproducibility of results. In addition, the side effects of steroid injections are common and significant. Telangiectasias, hypopigmentation, and skin atrophy had a reported incidence of 37% in one study.¹¹ Alternative therapies, such as laser or radia-

tion therapy, require significant hardware. The ideal treatment would have a low side effect profile and be cost effective and easy to administer without the need of elaborate hardware.

The interest in antineoplastic agents as a therapeutic modality is logical, because keloids have been shown to exist in a hypermetabolic state.^{9,12} Both in vitro and in vivo studies have confirmed that 5-FU inhibits collagen synthesis.¹³⁻¹⁷ There are a number of clinical reports in the literature regarding the efficacy of various antineoplastic drugs on modification of scarring.^{16,18-20} However, many of these studies have either limited follow-up or small treatment numbers.^{11,16,21-35}

In an effort to find an alternative to intralesional triamcinolone, which caused significant skin atrophy, we investigated a 5-FU/steroid mixture. Our hypothesis was that the combination 5-FU/steroid mixture is superior for the treatment of keloids and reduces side effects. To our knowledge, there have been no quantitative long-term studies comparing 5-FU to triamcinolone.

METHODS

This study was conducted after institutional review board approval. Charts were reviewed for patients who received either a combination of 5-FU and triamcinolone or steroids alone from 1999 to 2006. All treatments were

From the Department of Plastic Surgery, Georgetown University Hospital, Washington, DC.

Table. Scar reduction by amount of follow-up time

	Follow-up			Overall
	6 mos-2 yrs	2-4 yrs	4-6 yrs	
Percent scar reduction with 5-FU/triamcinolone without excision	84% (n = 18)	82% (n = 19)	78% (n = 15)	81% (n = 52)
Percent scar reduction with 5-FU/triamcinolone with excision	95% (n = 9)	92% (n = 9)	90% (n = 6)	92% (n = 24)
Percent scar reduction with triamcinolone with excision	78% (n = 8)	74% (n = 13)	67% (n = 5)	73% (n = 2)

5-FU = 5-fluorouracil.

Overall comparison values were statistically significant ($P = .05$) based on analysis of variance.

performed by the senior author (SPD). The follow-up period ranged from 6 months to 6 years (Table). Patients were stratified into 3 groups: (1) combination 5-FU/triamcinolone without excision; (2) combination 5-FU/triamcinolone with excision; and (3) triamcinolone injection with excision. Patients who received triamcinolone excision were randomized as a group of consecutive patients during the study period. Patients who received 5-FU/triamcinolone without excision were not randomized in this study because they were deemed as inappropriate candidates for surgical excision (by SPD). Because there were only a small number of patients who received triamcinolone injections alone, this group was excluded from the study.

For patients undergoing keloid excision, injections were performed intraoperatively and repeated at 2, 4, and 6 weeks postoperatively. Nonsurgical patients received injections at an average of 4-week intervals. Because the treatment of keloids is multifactorially determined, the antineoplastic agent was varied and other modalities were used equally among the groups. A mixture of 75% 5-FU and 25% triamcinolone was used; 0.1 mL of solution per centimeter of lesion was injected. However, if steroid-related side effects were noted, the steroid concentration was reduced from 40 mg/mL to 10 mg/mL.

Charts were reviewed for percentage change in lesion size and evolution of symptoms, including pain and pruritus. Adverse effects such as thinning and telangiectasias were documented. Results were evaluated by an independent biostatistician applying analysis of variance (ANOVA) and χ^2 analysis with S-Plus software (version 4.5; MathSoft, Inc., Needham, MA).

RESULTS

A total of 94 patients with 102 keloids were identified. Fifty-two keloids were treated with an intralesional injection of combination 5-FU/triamcinolone without excision. Twenty-four keloids were treated with combination 5-FU/triamcinolone with excision. Twenty-six keloids were treated with triamcinolone with excision.

Patients who underwent the 5-FU/steroid combination with excision had a 92% average reduction in lesion size compared with 73% in those patients who did not receive 5-FU. Patients who received intralesional 5-FU/steroid without excision had an average size reduction of 81%

(Table). These comparison values were statistically significant ($P = .05$) based on ANOVA.

Pair wise t tests were performed afterward, yielding the following point estimates for group differences: (1) triamcinolone + excision versus 5-FU + triamcinolone ($t = -1.0756$; degree of freedom [df] 576; $P = .2855$; confidence interval [CI], -0.23-0.07); (2) 5-FU + triamcinolone versus 5-FU + triamcinolone + excision ($t = -2.5011$; df = 74; $P = .0146$; CI, -0.20-0.02); and (3) triamcinolone + excision versus 5-FU + triamcinolone + excision ($t = -2.0181$; df = 48; $P = .0492$; CI, -0.38-0.0007).

When comparing patients who underwent surgical excision, there was a statistically significant reduction in keloid size if 5-FU was added to the triamcinolone injection ($P = .0492$).

Of the 76 keloids treated with 5-FU (either with or without excision), 26 were painful (34%) and 27 presented with pruritus (36%). Pain resolved in 92% of these cases, with 2 patients reporting mildly increased pain after treatment. Pruritus resolved in 93% of patients, with 1 patient reporting no change and 1 patient reporting increased pruritus. There were not enough patients with these pretreatment symptoms in the steroid only group to present a significant comparison group.

The incidence of adverse effects in all patients who received 5-FU treatment was 23% as compared with 15% in the steroid only group. However, this difference was not statistically significant ($P = .37$) based on χ^2 testing. The most common adverse effect in both groups was the development of telangiectasias. Representative cases of the more intractable keloids in this study group are presented in Figures 1 through 6, comprised of patients that failed previous triamcinolone, excision, and radiation therapy and patients manifesting adverse effects with the treatment regimen.

DISCUSSION

Keloids are a common and difficult problem to treat. A wide variety of modalities have been used to treat keloids, reflecting a lack of consensus on an ideal regimen. Previous attempts to modulate wound healing with interferon had failed with greater efficacy of steroid alone.³⁶ However, triamcinolone has several shortcomings. Keloid recurrence is significant, and a review of the

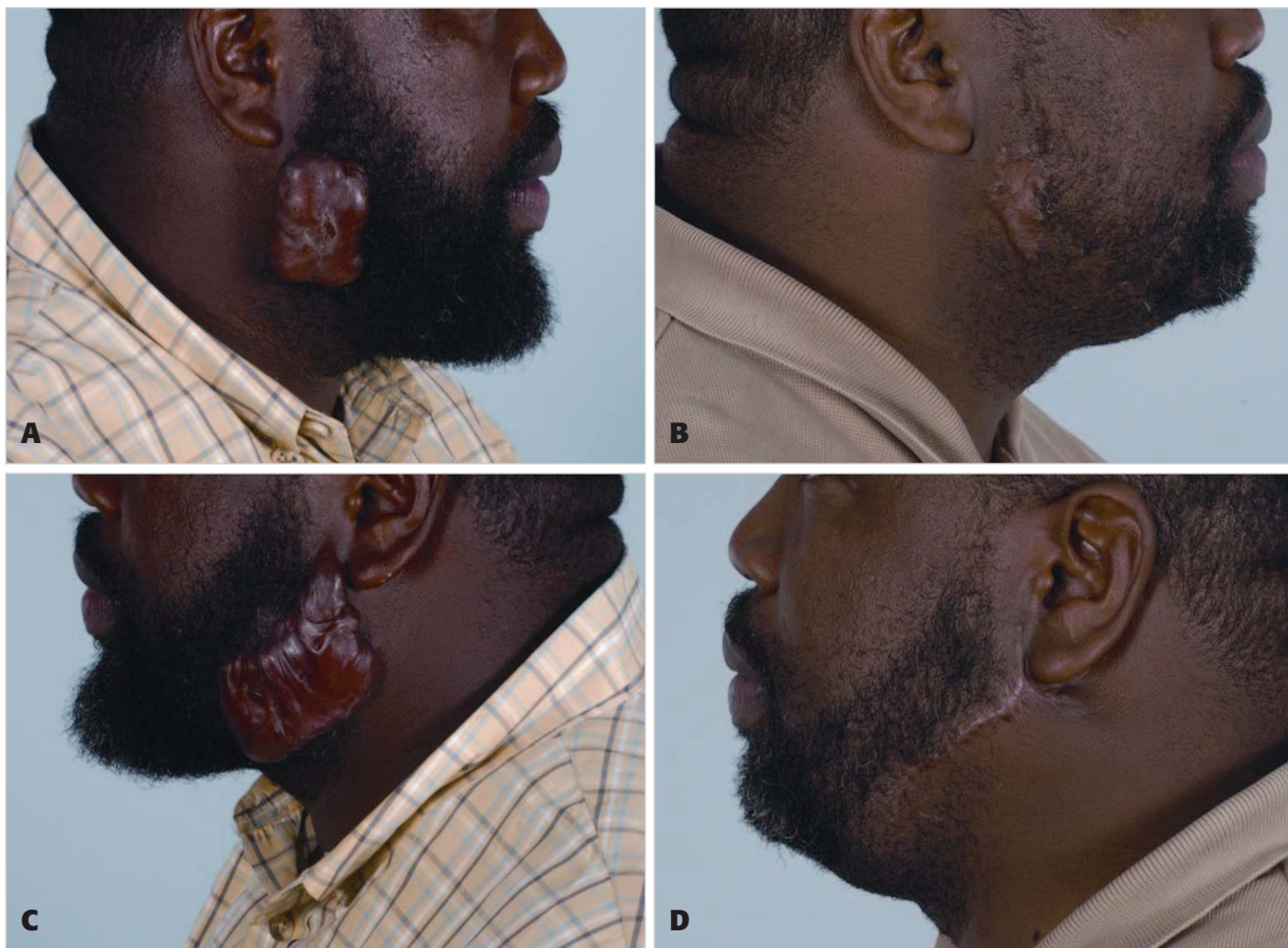

Figure 1. **A, C,** Preoperative views of a 43-year-old man with recurrent keloids on both sides of the jaw line. **B, D,** Postoperative views 20 months after successful treatment with surgical excision, injection of combination 5-fluorouracil and triamcinolone, and single-dose 800 cGy radiation. A total of 5 injections were administered.

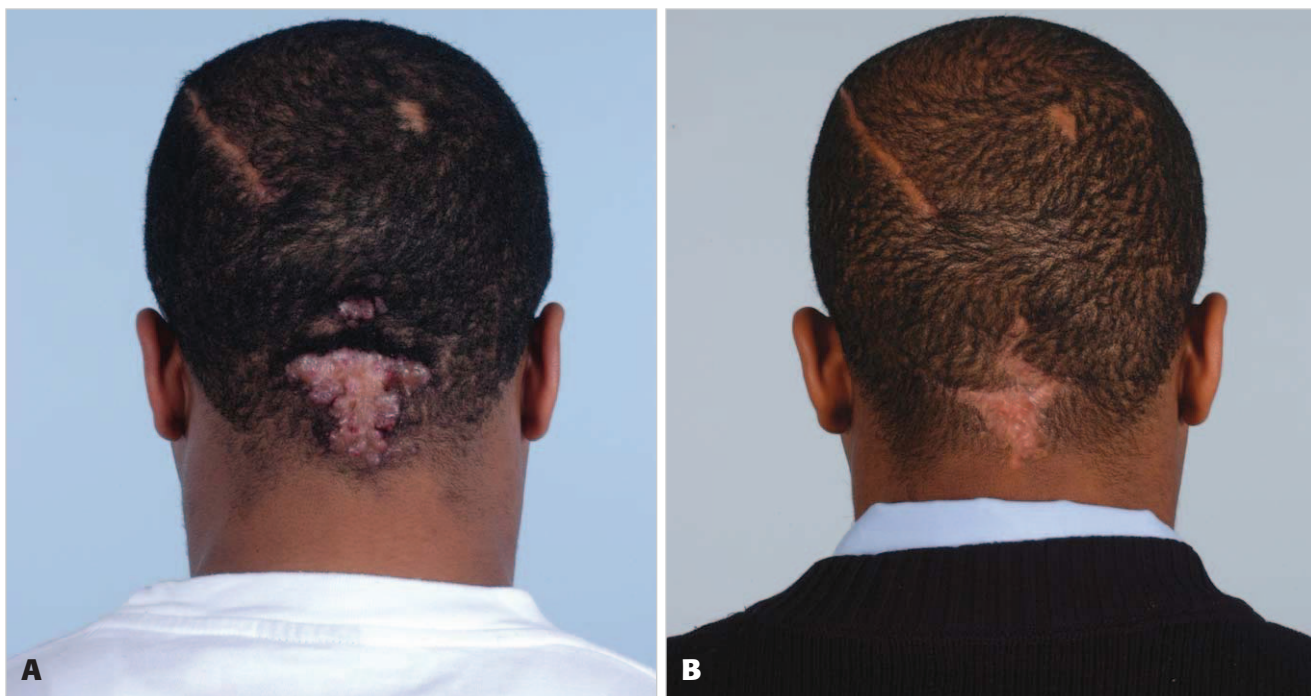

Figure 2. **A,** Preoperative view of a 35-year-old man presenting with recurrent keloids after failed excision, triamcinolone, and radiation treatments. **B,** Postoperative view 6 months after excision, 5-fluorouracil and triamcinolone injection, and single-dose 800 cGy radiation. A widened scar resulted from postoperative wound dehiscence, but there is no evidence of keloid recurrence at 6 months.

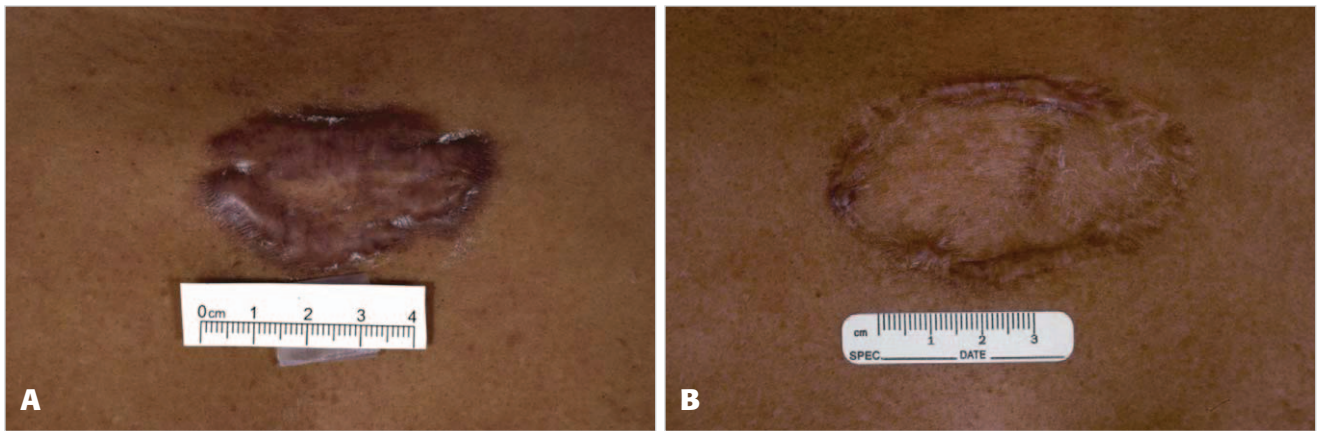


Figure 3. **A,** Preoperative view of a painful keloid located on the chest of a 48-year-old woman. **B,** Postoperative presentation 30 months after excision, Integra, and staged full-thickness skin graft with intralesional 5-fluorouracil and triamcinolone and single-dose 800 cGy radiation. The pain completely resolved and the scar is stable.

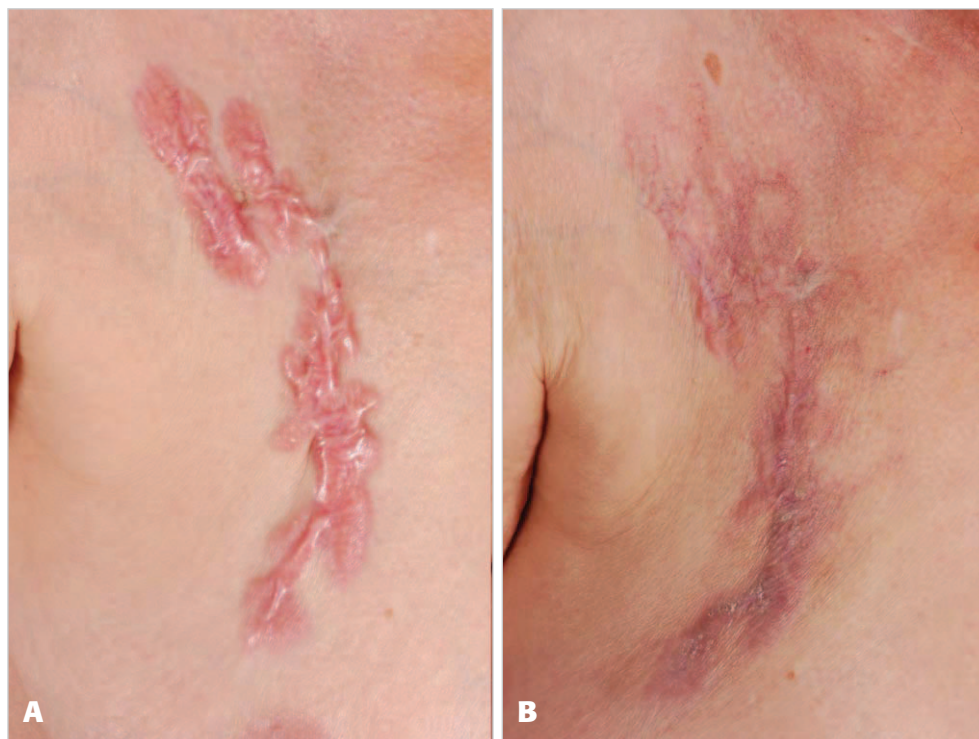


Figure 4. **A,** Pretreatment view of a very painful and pruritic keloid, with intermittent excoriations and breakdown from scratching, on the chest of a 79-year-old woman. **B,** Posttreatment view 7 months after intralesional 5-fluorouracil/triamcinolone was administered weekly for the first 3 weeks, then every 6 weeks for a total of 6 injections. The pain and severe pruritus have resolved with flattening of the keloid.

literature yields an inconsistent range of success rates. The senior author (SPD) began using 5-FU in 1999 in patients that failed traditional intralesional triamcinolone, excision, and radiation therapy. The results of this study appear to support anecdotal observations of improved efficacy using 5-FU.

The specific pathogenesis of keloids remains controversial. However, their hypermetabolic nature, which yields abnormally high levels of collagen, makes anti-neoplastic agents an appealing treatment option.^{9,10,12} A study by Bulstrode et al.¹⁵ revealed that 5-FU selectively inhibits collagen synthesis. 5-FU interrupts both DNA and RNA synthesis at several levels, including the inhibi-

tion of thymidylate synthetase and the production of toxic metabolites.^{15,37-39}

There are a number of clinical studies on the efficacy of 5-FU in keloid treatment that revealed promising results.^{11,21,23,25-27,29,34} Fitzpatrick²³ was the first to publish an anecdotal report of a vast experience with 5-FU, although there are no quantitative data or control group presented. Fitzpatrick's regimen used a 9:1 ratio of 5-FU to steroid. The small concentration of triamcinolone does not have any additive therapeutic effect, but Fitzpatrick stated that it reduces the side effect of erythema that may occur with pure 5-FU injection. One recent prospective study revealed a statistically significant

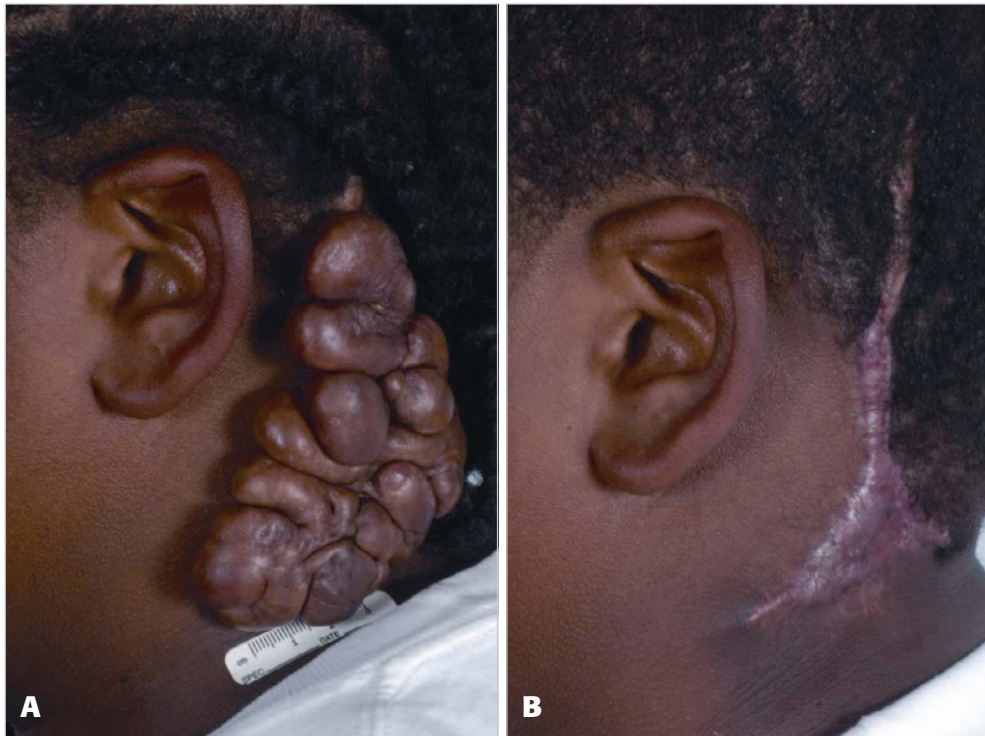

Figure 5. A, Preoperative view of a painful, recurrent keloid located in the left posterior auricular region in a 16-year-old male. **B,** Postoperative results 5 months after surgical excision and combination 5-fluorouracil/triamcinolone. The pain has completely resolved, but there is an area of early recurrence that will require additional injections.

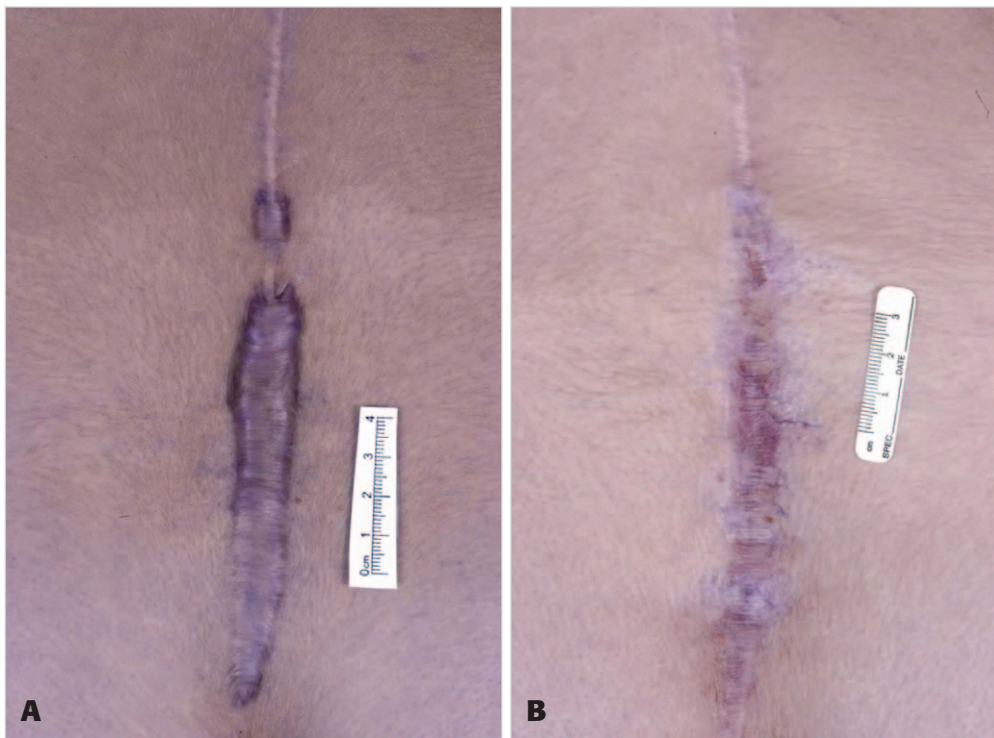


Figure 6. A, Pretreatment view of a recurrent keloid in the lower back of a 25-year-old woman who had undergone previous treatment with excision, radiation, and steroid injection. **B,** Posttreatment view 16 months after undergoing 4 serial injections of a mixture of 75% 5-fluorouracil/25% triamcinolone. Although there is regression of the keloid, there are scattered areas of dermal atrophy and telangiectasia that are representative of the most common type of adverse effect seen with this regimen.

improvement in efficacy of 5-FU over triamcinolone.¹¹ However, patient follow-up in this study was limited to 12 weeks, which is grossly inadequate because keloids can recur from months to years after treatment.

Several studies have shown 5-FU to be a safe treatment although it should be avoided in pregnant women.^{16,21,24-26,29,34,40} 5-FU was used in 1 pediatric patient in this study, without any adverse effects, with

approval from the Lombardi Cancer Center Department of Pediatric Oncology.

There is a broad range of reported dosing intervals, from several injections per week to once a month. Examining the basic science literature, a paper by Occleston⁴⁰ has shown that type I collagen, fibronectin, and cell migration were inhibited by 5-FU for 48 days. An in vivo study by Uppal et al.³⁴ suggests that the effect of 5-FU on fibroblasts is apparent at 4 weeks posttreatment, although this finding was not statistically significant because of the small test group of patients. These findings suggest a standard dosing regimen spaced 4 weeks apart may be an appropriate starting point for efficacy trials.

Regarding the incidence of adverse effects, there was no statistically significant difference between the 5-FU and steroid only groups. However, one could speculate the telangiectasias in the 5-FU group were likely caused by the steroid component. Nanda et al.²⁹ prospectively studied the use of pure 5-FU on keloids and did not have any occurrence of hypopigmentation or telangiectasias. This reduced side effect profile warrants further evaluation of 5-FU. Adverse effects may be decreased by reducing the steroid component and using a 9:1 mixture as advocated by Fitzpatrick.²³

CONCLUSIONS

The results of this study suggest that 5-FU in combination with triamcinolone may be superior to triamcinolone alone. Although this study is limited by its retrospective nature, this review, the supporting basic scientific data, and anecdotal observations warrant closer investigation. The success of 5-FU in those cases that failed steroid treatment is particularly significant. The goal is to establish an ideal mixture of 5-FU and triamcinolone that maintains efficacy while minimizing side effects likely related to the steroid component. We are currently conducting a prospective, controlled randomized study using combination 5-FU/triamcinolone with various dosing schedules to establish an optimal regimen. Long-term prospective randomized studies are needed in the area of keloid treatment. ▀

DISCLOSURES

The authors have no financial interest in and received no compensation from manufacturers of products mentioned in this article. There was no funding received for this study.

REFERENCES

1. Al-Attar A, Mess S, Thomassen JM, Kauffman CL, Davison SP. Keloid pathogenesis and treatment. *Plast Reconstr Surg* 2006;117:286–300.
2. Berman B, Flores F. Recurrence rates of excised keloids treated with postoperative triamcinolone acetonide injections or interferon alfa-2b injections. *J Am Acad Dermatol* 1997;37:755–757.
3. Ketchum LD. Hypertrophic scars and keloids. *Clin Plast Surg* 1977;4:301–310.
4. Oluwasanmi JO. Keloids in the African. *Clin Plast Surg* 1974;1:179–195.
5. Griffith BH. The treatment of keloids with triamcinolone acetonide. *Plast Reconstr Surg* 1966;38:202–208.
6. Griffith BH, Monroe CW, McKinney P. A follow-up study on the treatment of keloids with triamcinolone acetonide. *Plast Reconstr Surg* 1970;46:145–150.
7. Muneuchi G, Suzuki S, Onodera M, Ito O, Hata Y, Igawa HH. Long-term outcome of intralesional injection of triamcinolone acetonide for the treatment of keloid scars in Asian patients. *Scand J Plast Reconstr Surg Hand Surg* 2006;40:111–116.
8. Tang YW. Intra- and postoperative steroid injections for keloids and hypertrophic scars. *Br J Plast Surg* 1992;45:371–373.
9. Ueda K, Furuya E, Yasuda Y, Oba S, Tajima S. Keloids have continuous high metabolic activity. *Plast Reconstr Surg* 1999;104:694–698.
10. Younai S, Nichter LS, Wellisz T, Reinisch J, Nimni ME, Tuan TL. Modulation of collagen synthesis by transforming growth factor-beta in keloid and hypertrophic scar fibroblasts. *Ann Plast Surg* 1994;33:148–151.
11. Asilian A, Darougeheh A, Shariati F. New combination of triamcinolone, 5-fluorouracil, and pulsed-dye laser for treatment of keloid and hypertrophic scars. *Dermatol Surg* 2006;32:907–915.
12. Fujiwara M, Muragaki Y, Ooshima A. Keloid-derived fibroblasts show increased secretion of factors involved in collagen turnover and depend on matrix metalloproteinase for migration. *Br J Dermatol* 2005;153:295–300.
13. Benkhaial GS, Cheng KM, Shah RM. Effects of 5-fluorouracil on collagen synthesis during quail secondary palate development. *J Craniofac Genet Dev Biol* 1993;13:6–17.
14. Ben-Khaial GS, Shah RM. Effects of 5-fluorouracil on collagen synthesis in the developing palate of hamster. *Anticancer Drugs* 1994;5:99–104.
15. Bulstrode NW, Mudera V, McGrouther DA, Grobbelaar AO, Cambrey AD. 5-fluorouracil selectively inhibits collagen synthesis. *Plast Reconstr Surg* 2005;116:209–221.
16. Khaw PT, Sherwood MB, MacKay SL, Rossi MJ, Schultz G. Five-minute treatments with fluorouracil, floxuridine, and mitomycin have long-term effects on human Tenon's capsule fibroblasts. *Arch Ophthalmol* 1992;110:1150–1154.
17. de Waard JW, de Man BM, Wobbes T, van der Linden CJ, Hendriks T. Inhibition of fibroblast collagen synthesis and proliferation by levamisole and 5-fluorouracil. *Eur J Cancer* 1998;34:162–167.
18. Heuer DK, Parrish RK 2nd, Gressel MG, Hodapp E, Palmberg PF, Anderson DR. 5-fluorouracil and glaucoma filtering surgery. II. A pilot study. *Ophthalmology* 1984;91:384–394.
19. Rockwood EJ, Parrish RK 2nd, Heuer DK, Skuta GL, Hodapp E, Palmberg PF, et al. Glaucoma filtering surgery with 5-fluorouracil. *Ophthalmology* 1987;94:1071–1078.
20. Tsai JC, Feuer WJ, Parrish RK 2nd, Grajewski AL. 5-Fluorouracil filtering surgery and neovascular glaucoma. Long-term follow-up of the original pilot study. *Ophthalmology* 1995;102:887–892.
21. Apikian M, Goodman G. Intralesional 5-fluorouracil in the treatment of keloid scars. *Australas J Dermatol* 2004;45:140–143.
22. Espana A, Solano T, Quintanilla E. Bleomycin in the treatment of keloids and hypertrophic scars by multiple needle punctures. *Dermatol Surg* 2001;27:23–27.
23. Fitzpatrick RE. Treatment of inflamed hypertrophic scars using intralesional 5-FU. *Dermatol Surg* 1999;25:224–232.
24. Gupta S, Kalra A. Efficacy and safety of intralesional 5-fluorouracil in the treatment of keloids. *Dermatology* 2002;204:130–132.
25. Kontochristopoulos G, Stefanaki C, Panagiotopoulos A, Stefanaki K, Argyrakos T, Petridis A, et al. Intralesional 5-fluorouracil in the treatment of keloids: An open clinical and histopathologic study. *J Am Acad Dermatol* 2005;52:474–479.
26. Lebowhl M. From the literature: Intralesional 5-FU in the treatment of hypertrophic scars and keloids: Clinical experience. *J Am Acad Dermatol* 2000;42:677.
27. Manuskiaiti W, Fitzpatrick RE. Treatment response of keloidal and hypertrophic sternotomy scars: Comparison among intralesional corticosteroid, 5-fluorouracil, and 585-nm flashlamp-pumped pulsed-dye laser treatments. *Arch Dermatol* 2002;138:1149–1155.
28. Meier K, Nanney LB. Emerging new drugs for scar reduction. *Expert Opin Emerg Drugs* 2006;11:39–47.

29. Nanda S, Reddy BS. Intralesional 5-fluorouracil as a treatment modality of keloids. *Dermatol Surg* 2004;30:54–56.
30. Sanders KW, Gage-White L, Stucker FJ. Topical mitomycin C in the prevention of keloid scar recurrence. *Arch Facial Plast Surg* 2005;7:172–175.
31. Saray Y, Gulec AT. Treatment of keloids and hypertrophic scars with dermojet injections of bleomycin: A preliminary study. *Int J Dermatol* 2005;44:777–784.
32. Simman R, Alani H, Williams F. Effect of mitomycin C on keloid fibroblasts: An in vitro study. *Ann Plast Surg* 2003;50:71–76.
33. Talmi YP, Orenstein A, Wolf M, Kronenberg J. Use of mitomycin C for treatment of keloid: A preliminary report. *Otolaryngol Head Neck Surg* 2005;132:598–601.
34. Uppal RS, Khan U, Kakar S, Talas G, Chapman P, McGrouther AD. The effects of a single dose of 5-fluorouracil on keloid scars: A clinical trial of timed wound irrigation after extralesional excision. *Plast Reconstr Surg* 2001;108:1218–1224.
35. Wu XL, Liu W, Cao YL. Clinical study on keloid treatment with intralesional injection of low concentration 5-fluorouracil. *Zhonghua Zheng Xing Wai Ke Za Zhi* 2006;22:44–46 (in Chinese).
36. Davison SP, Mess S, Kauffman LC, Al-Attar A. Ineffective treatment of keloids with interferon alpha-2b. *Plast Reconstr Surg* 2006;117:247–252.
37. Bender RA, Zwelling LA, Doroshow JH, Locker GY, Hande KR, Murinson DS, et al. Antineoplastic drugs: Clinical pharmacology and therapeutic use. *Drugs* 1978;16:46–87.
38. Ghoshal K, Jacob ST. An alternative molecular mechanism of action of 5-fluorouracil, a potent anticancer drug. *Biochem Pharmacol* 1997;53:1569–1575.
39. Johnston PG, Takimoto CH, Grem JL, Chabner BA, Allegra CJ, Chu E. Antimetabolites. *Cancer Chemother Biol Response Modif* 1996;16:1–27.
40. Ocleston NL, Daniels JT, Tarnuzzer RW, Sethi KK, Alexander RA, Bhattacharya SS, et al. Single exposures to antiproliferatives: Long-term effects on ocular fibroblast wound-healing behavior. *Invest Ophthalmol Vis Sci* 1997;38:1998–2007.

Accepted for publication November 14, 2008.

Reprint requests: Steven Paul Davison, DDS, MD, Georgetown University Hospital, Department of Plastic Surgery, 1st floor PHC Bldg., 3800 Reservoir Rd., NW, Washington, DC 20007. E-mail: spd2@gunet.georgetown.edu.

Copyright © 2009 by The American Society for Aesthetic Plastic Surgery, Inc. 1090-820X/\$36.00

doi:10.1016/j.asj.2008.11.006
