

Today
News
Reference
Education
Log In
Register



Labiaplasty and Labia Minora Reduction Treatment & Management

- Author: Steven P Davison, DDS, MD; Chief Editor: Jorge I de la Torre, MD, FACS [more...](#)

Updated: May 2, 2014

Medical Therapy

No medical management is available for labial hypertrophy.

Surgical Therapy

Labiaplasty surgery can be successfully performed under local anesthesia, sedation, or general anesthesia. The authors prefer to use local anesthesia for 3 main reasons. First, at critical points in the surgery, the awake patient can be involved in determining the amount of resection. This improves patient satisfaction and decreases the need for revisions. Second, local anesthesia allows the patient to escort herself to and from surgery, therefore eliminating the need for another person to care for them while undergoing this sensitive procedure. Third, there is a significant cost reduction without anesthesia fees, making this price-point-sensitive procedure accessible to more individuals.

Surgical site preparation and draping are standard. The authors have found povidone-iodine solution (Betadine) to be minimally reactive and very effective.

Local anesthesia starts with the application of a topical anesthetic such as BLT cream, which contains benzocaine (20%), lidocaine (6%), and tetracaine (4%). The thin mucosa of the labia allows rapid penetration of the topical anesthetic, making it more analogous to dental than dermal topical therapy. Then, 5-10 mL per side of 1% lidocaine with 1:100,000 epinephrine is injected with an ultrafine (31-gauge) needle, maintaining local anesthesia for up to 2 hours.^[11] Local anesthesia with lidocaine should also be used during general or sedation anesthesia for added vasoconstriction and postoperative pain control.

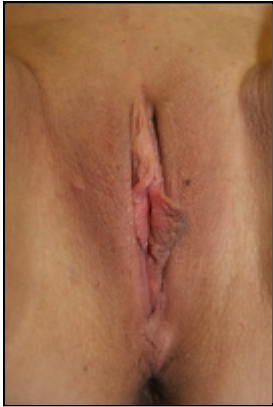As postoperative bleeding is a risk, hand-held thermocautery or electrocautery coagulation is highly recommended to reduce bleeding risk from resected mucosal edges.

Postoperative pain occasionally requires moderate narcotics such as hydrocodone or acetaminophen with codeine.

Amputation technique

The amputation technique (see images below) is also referred to as the trim/strip method, "clip and snip," or linear labiaplasty. This technique is the simplest of the labia reduction surgeries and is often preferred when the labial hypertrophy is localized.^[14] The excess skin on the labia minora is amputated and the new open edge is sutured closed. A proposed benefit of this technique is pinker labial edges that lie within the labia majora folds^[12]; others

may consider this detrimental. The amputation technique is limited in that it greatly alters the natural appearance of the labia minora.^[6] This technique presents a risk for nerve end interruption and results in the loss of the pigmented skin/mucosal margin and the natural edge of the labia minora.



This unilateral hypertrophy of the left labia minora can be addressed with the labiaplasty amputation technique.

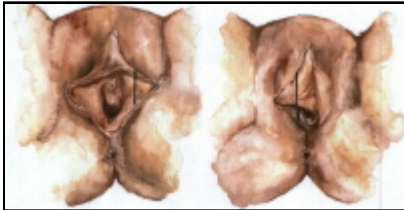
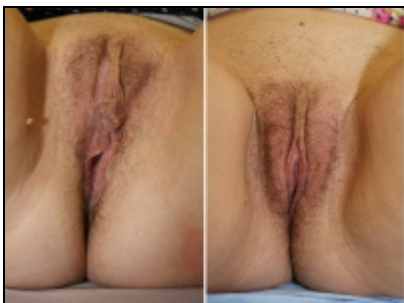

Diagram of amputation technique.

Wedge technique

The greatest evolution in labiaplasty involves the wedge technique (see image below). In this technique, a portion of the labial edge is excised and the “dog-ear” excision is carried into natural creases of the labial folds. The 3 types of wedges are anterior, central, and posterior. These techniques maintain the natural mucosa and skin edge, preserve tumescence and sensation, and maximize the aesthetic results.^[15] Common features are often deepithelialization of the wedge, leaving the submucosal lymphatics and nerves intact. A reported disadvantage of this technique is the potential damage to nerves along the edge of the removed wedge.^[12]

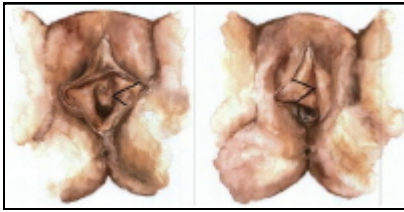

Wedge excision results. Before (left) and 3 months after (right) a wedge excision labiaplasty for moderate labia hypertrophy, allowing for preservation of the natural edge.

Central wedge

There are 3 described techniques for excising a central wedge (see image below). The first technique involves a deepithelialization of the central wedge and preserving the underlying submucosa.^[4] A second technique involves a full-thickness resection of a V-shaped wedge of excess labial tissue.^[12, 3] This resection maintains the natural edge and minimizes the scar. The third approach is the 90° Z-plasty.^[16] This wedge technique reduces tension on the

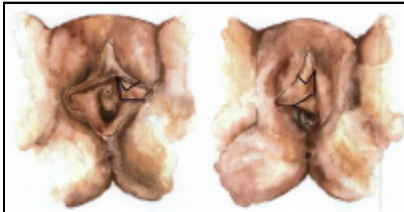suture line, further minimizing the scar.^[15] The advantage of the central wedge is simplicity. The main drawback is limited allowance to aesthetically alter the labial appearance.



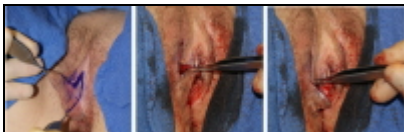Central wedge technique.

Anterior wedge

Labial hypertrophy may also be corrected using an anterior wedge excision (see images below). This technique resects anterior mucosa and skin. The dog-ear is extended into the labia minora and labia majora crease. This is well hidden and provides optimal aesthetic results.^[6] The amount of resection is variable; clinical judgment is needed to prevent excessive resection and narrowing of the labia. Additionally, the anterior wedge technique has the advantage of pulling down some of the excess clitoral hood into the labial crease.



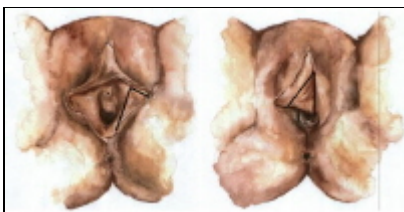
Anterior wedge technique with labial crease extension.



Anterior wedge technique. (Left) The dog ear is extended into the labial crease. (Center) The labia is approximated centrally. (Right) The dog ear is closed anteriorly.

Posterior wedge

This technique removes the posterior fornix labia, leaving an intact labial rim (see image below).^[17] A drawback of the posterior wedge technique is the length of the flap and the distance the blood supply must travel.



Posterior wedge technique.

All of these techniques preserve the mucosal-to-skin presentation, between labia tissue and the surrounding skin. Each is adaptable to the amount of resection necessary, but limited in that the incision line is placed directly in the labia, as opposed to a labial fold. A mitigating benefit of these techniques is the incision is hard to see, even on the labial edge.

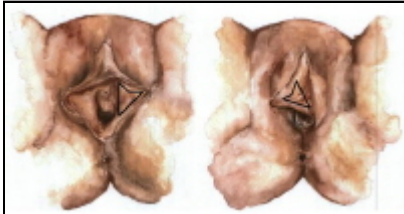Deepithelialization technique

This technique involves the deepithelialization of the center region of the labia while preserving the natural free edge

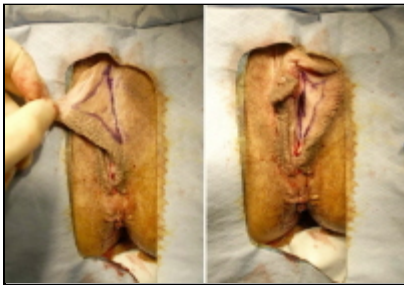of the labia minora.^[7] The design of the deepithelialization as a tripoint allows anterior, posterior, and vertical reduction. The length of the wedge excised should not be longer than the length from the clitoral hood to the posterior side of the labia minora.^[4]

Benefits of using this technique include nerve, tissue, and lymphatic preservation.^[4] There is minimal to no blood loss using this technique.^[4] Although the central wedge technique removes a central portion of the leading edge, the deepithelialization technique removes a portion of the central labia while preserving the leading edge. For this reason, this technique is limited in the amount of tissue that can be removed and there is a risk of recurrent hypertrophy with the deepithelialization technique.

See the images below.



Deepithelialization technique.



Central deepithelialization technique. The patterns drawn out on the mucosa and skin sides of the labia illustrate the central deepithelialization technique. The tristar excision as a deepithelialization maximizes nerve and vascular supply to the edge while minimizing dog-ears.

Laser labiaplasty

Laser techniques are very similar to deepithelializing methods, using a laser rather than a scalpel. Both erbium and carbon dioxide lasers can be used.^[15] Proposed benefits of laser therapy are reduced blood loss and enhanced healing,^[15] although most of the benefit may be marketing. Limitations of this technique include higher risk for epidermal inclusion cysts.

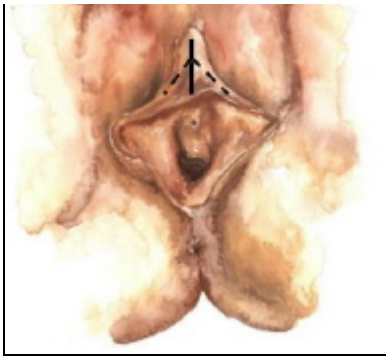
Additional procedures

Clitoral unhooding

Composite reductions of the labia are often performed to ensure a balanced and symmetrical result. In this composite reduction, a labiaplasty is combined with clitoral unhooding. Clitoral unhooding reduces the amount or thickness of epithelial tissue surrounding the clitoris.^[18] From an anterior view, this can be aesthetically displeasing. The balance in technique is unhooding the clitoris without an unhooded clitoris. Excessive exposure leads to hypersensitivity, as well as the appearance of the microphallus.^[6]

The classic clitoral un-hooding is a modified Y-to-V technique. The clitoral hood is incised and the excess tissue on either side of the Y can be amputated, as depicted below.





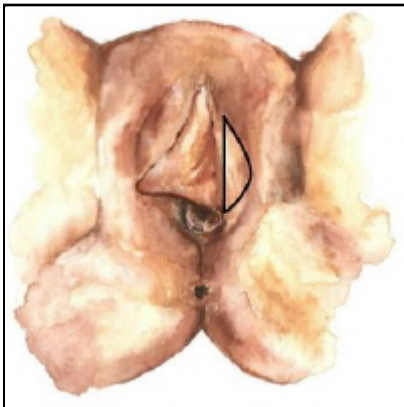
Clitoral unhooding Y-to-V technique.

An alternative to the clitoral unhooding technique is the clitoral tightening.^[11] In conjunction with a central wedge, wings of the anterior labia are advanced posterior and the clitoris is tightened posteriorly into the cleft.

Complications of the composite labial reductions are minimal and similar to those of any labiaplasty technique. In a 2013 study, 35% of patients who underwent the composite procedure experienced increased sexual excitability and no patients experienced prolonged pain.^[11]

Labia majora reduction

The problems of the labia majora are 2-fold: (1) atrophy of the fat and (2) excess skin. The solutions are fat grafting and surgical resection, respectively.^[11] If a patient has atrophy of fat in the labia majora, the author recommends injection of 10-15 mL of fat into each side of the labia majora, of which approximately 40-60% survives.^[19] The most common technique the authors use for a surgical resection of excess labia majora skin is an elliptical wedge on the inner edge of the labia, as shown below. This is designed to place the final closure into the labial crease.



Labia majora reduction technique with ellipse wedge.

G-spot alteration

Both fat grafting and fillers, such as Radiesse, can be applied to the anterior vaginal wall to enhance the perceived G-spot. Injections of fillers and/or collagen to the G-spot enhance the size, which should, in turn, increase sexual pleasure.^[1] One injection, G-Shot, uses hyaluronic acid off-label to increase the presumed G-spot size up to 100%.^[15] These injections can lead to bleeding, infection, urinary complications, and lack of sensitivity in the G-spot.

Monsplasty

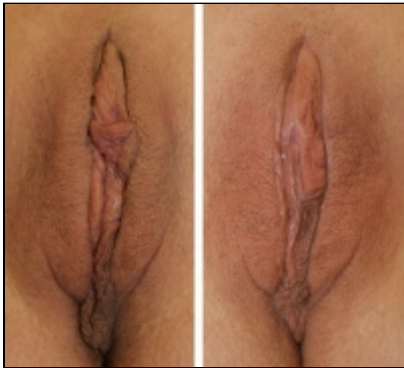The mons has also been an increasing region of focus in female genital cosmetic surgery (FGCS). Using a wedge excision method, wide mons are reduced.^[13] The procedure works well in combination with labiaplasty and/or abdominoplasty in patients who have experienced massive weight loss.

Authors' technique

The authors' technique reflects their overall cosmetic surgery philosophy, which is to tailor the operation to the problem or concern. They believe that no one technique is ideal for all patients. Therefore, specific techniques or combinations of techniques should be used on patients after their particular hypertrophic labia minora have been examined. We predominantly use a progressive anterior wedge excision. The closure line is situated at the anterior to mid third of the labia minora. The excess is removed from the central third. The dog-ear or scar excess is extended into the anterior labial crease. A clitoral unhooding is also performed as needed as a V-to-Y excision is used. Any excess tissue remaining on the transition from the clitoral hood to the labia minora is amputated.

For a patient who desires to keep the natural looking edge of the labia minor without a visible scar, the deepithelialization technique is recommended. The deepithelialization technique in combination with clamp resection should be used for patients with considerable excess skin.

The deep planes are closed with 4.0 or 5.0 Monocryl sutures and the labial edge is approximated with a 5.0 Vicryl Rapide. Any skin closure is performed with a 5.0 Vicryl Rapide subcuticular or a 5.0 fast-absorbing suture. Regardless of the technique used to reduce the labia minora, it is recommended that any long-acting sutures are used in a buried interrupted or running suture. Running sutures externally can lead to aesthetically poor results on the free edge of the labia minora, while the buried running suture can create a smooth free edge. This scalloped look to the free edge is hard to correct. See the image below.



Labiaplasty results. Before (left) and 1 year after (right) a successful labiaplasty with wedge technique, labia majora reduction, clitoral unhooding, and posterior fornix release. If desired by the patient, the amputation technique can be used on the left labia minora to enhance the results and create color symmetry.

Preoperative Details

All patients are seen preoperatively to evaluate the best approach for labia minora reduction. Patients are evaluated while standing and marked in the lithotomy position. The presence of pubic hair is irrelevant for the procedure. The patient should not shave immediately prior to the operation to avoid increased infection risks.

Intraoperative Details

Although the procedure can be conducted under local, sedation, or general anesthesia, the authors prefer to use local anesthesia if possible. Topical cream is applied 30 minutes prior to the start of the procedure. The authors use 10-20 mL total of 1% lidocaine with 1:100,000 epinephrine as the local anesthetic. The procedure is conducted with the patient in the lithotomy position.

Postoperative Details

All labiaplasty procedures are same-day surgeries. Under local anesthesia, the patient may not require a responsible adult following the procedure. This allows her the option to maintain utmost privacy for this sensitive procedure.

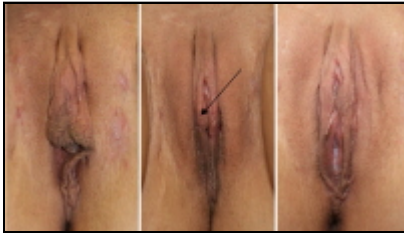Topical antibiotic ointment is applied to the incision immediately following surgery and applied 3 times a day for the first 5 postoperative days. If bleeding occurs, the patient should apply pressure for 10 minutes with a sanitary pad. The patient may choose to use a sanitary pad at all times in her undergarments until the incisions have healed. The patient may begin taking a bath 48 hours after the procedure.

Follow-up

Patients are seen postoperatively at 1 week and 1 month following their procedure. The patient may return to normal work and exercise in 3-4 days. However, it is recommended that the patient avoid the use of tampons or tight underwear and clothing for 4 weeks. Similarly, the patient should avoid sexual intercourse for 4 weeks.

Complications

Complications are uncommon for the labiaplasty procedure. Wound dehiscence and bleeding are early complications that have been documented.^[9] Smoking predisposes patients to dehiscence or wound breakdown (see the image below). The most common complication is patient dissatisfaction with the final results. Communication regarding the patient's expectations is critical. In the authors' practice, the frequency of revisions has reduced after the transition to using local anesthesia, which allows active patient involvement in determining the final resection.



Smoking predisposes patients to dehiscence. This labia minora reduction patient (left) was a smoker. She smoked during the 2 preoperative and postoperative weeks, causing dehiscence to the left labial crease (center). The dehiscence had no long-term complications on the result (right).

Outcome and Prognosis

In the authors' experience, patients are generally well satisfied with their results after having a labiaplasty. According to a study of female genital plastic surgery including labiaplasty and vaginoplasty patients, 91.6% of women who underwent surgery reported an increase in sexual function following the procedure.^[20] A similar study in 2000 reported that 80% of the patients were satisfied with their results.^[9] Additionally, a study of labial reductions in 2012 reported 92.3% of women had functional problems corrected, while 89.7% of patients were relieved of psychological distress.^[11] One of the problems with evaluating patient satisfaction with this procedure is the limited long-term follow-up. Patients rarely return for evaluation after their 1-month check-up, despite being advised to make and attend follow-up appointments.

Future and Controversies

Cosmetic alterations or rejuvenation of female genitalia is a growing topic in plastic surgery literature and practice. Plastic surgery literature identifies changing hair patterns and media exposure as additional factors contributing to the growth in female genital cosmetic surgery (FGCS) trends.^[2] As the awareness and desire for rejuvenated genitalia increases, so will of the frequency of procedures.

Much of the discussion surrounding FGCS involves the ethical concerns. Some of the macroethical issues include social pressures, limited economics, and defining necessary procedures.^[2] Microethical issues include proper informed consent and knowledge of normal female genitalia anatomy.^[2] Finally, although labiaplasties are not

mutilation surgeries, they have been correlated with female genital mutilation. Unlike genital mutilation, labiaplasties are not intended to decrease natural sexual function, nor do they restrict any basic human rights.^[2] Again, labiaplasty is separate from genital mutilation because this elective FGCS is an operation of choice and not an operation intended to decrease sexual function against the patient's will.

Contributor Information and Disclosures

Author

Steven P Davison, DDS, MD Private Practice, President, DAVinci Plastic Surgery; Professor, Department of Surgery, Division of Plastic Surgery, Georgetown University Medical Center

Steven P Davison, DDS, MD is a member of the following medical societies: [American Academy of Facial Plastic and Reconstructive Surgery](#), [American Academy of Otolaryngology-Head and Neck Surgery](#), [American Association of Plastic Surgeons](#), [American College of Surgeons](#), [American Medical Association](#), [American Society for Reconstructive Microsurgery](#), [American Society of Aesthetic Plastic Surgery](#), [American Society of Maxillofacial Surgeons](#), and [American Society of Plastic and Reconstructive Surgery](#)

Disclosure: Nothing to disclose.

Coauthor(s)

Cassandra L Baker Medical Assistant, DAVinci Plastic Surgery

Disclosure: Nothing to disclose.

Justin E West, MD Medical Director, Finesse Plastic Surgery; Director of Plastic and Reconstructive Surgery, Breastlink

Justin E West, MD is a member of the following medical societies: [American Society of Plastic Surgeons](#)

Disclosure: Nothing to disclose.

Specialty Editor Board

Gregory Gary Caputy, MD, PhD, FICS Chief Surgeon, Aesthetica

Gregory Gary Caputy, MD, PhD, FICS is a member of the following medical societies: [American Society for Laser Medicine and Surgery](#), [International College of Surgeons](#), [International College of Surgeons US Section](#), [Pan-Pacific Surgical Association](#), and [Wound Healing Society](#)

Disclosure: Advantage Wound Care Salary Employment

Francisco Talavera, PharmD, PhD Adjunct Assistant Professor, University of Nebraska Medical Center College of Pharmacy; Editor-in-Chief, Medscape Drug Reference

Disclosure: Medscape Salary Employment

Wayne Karl Stadelmann, MD Stadelmann Plastic Surgery, PC

Wayne Karl Stadelmann, MD is a member of the following medical societies: [Alpha Omega Alpha](#), [American College of Surgeons](#), [American Society of Plastic Surgeons](#), [New Hampshire Medical Society](#), [Northeastern Society of Plastic Surgeons](#), and [Phi Beta Kappa](#)

Disclosure: Nothing to disclose.

Nicolas (Nick) G Slenkovich, MD Director, Colorado Plastic Surgery Center

Nicolas (Nick) G Slenkovich, MD is a member of the following medical societies: [American Academy of Otolaryngology-Head and Neck Surgery](#), [American College of Surgeons](#), [American Medical Association](#), [American Society of Aesthetic Plastic Surgery](#), [American Society of Plastic Surgeons](#), and [Colorado Medical Society](#)

Disclosure: Nothing to disclose.

Chief Editor

Jorge I de la Torre, MD, FACS Professor of Surgery and Physical Medicine and Rehabilitation, Chief, Division of Plastic Surgery, Residency Program Director, University of Alabama at Birmingham School of Medicine; Director, Center for Advanced Surgical Aesthetics

Jorge I de la Torre, MD, FACS is a member of the following medical societies: [American Association of Plastic Surgeons](#), [American Burn Association](#), [American College of Surgeons](#), [American Medical Association](#), [American Society for Laser Medicine and Surgery](#), [American Society for Reconstructive Microsurgery](#), [American Society of Maxillofacial Surgeons](#), [American Society of Plastic Surgeons](#), [Association for Academic Surgery](#), and [Medical Association of the State of Alabama](#)

Disclosure: Nothing to disclose.

Additional Contributors

The authors wish to thank our patients for allowing the use of their photographs for this article, as well as our artist for the illustrations.

References

1. Rao N, Aparajita, Sharma N. Current trends in female genital cosmetic surgery. *Apollo Medicine*. 2012;3(5):219-23.
2. Cain JM, Iglesia CB, Dickens B, Montgomery O. Body enhancement through female genital cosmetic surgery creates ethical and rights dilemmas. *Int J Gynaecol Obstet*. Aug 2013;122(2):169-72. [Medline].
3. Reddy J, Laufer MR. Hypertrophic labia minora. *J Pediatr Adolesc Gynecol*. Feb 2010;23(1):3-6. [Medline].
4. Cao YJ, Li FY, Li SK, Zhou CD, Hu JT, Ding J, et al. A modified method of labia minora reduction: the de-epithelialised reduction of the central and posterior labia minora. *J Plast Reconstr Aesthet Surg*. Aug 2012;65(8):1096-102. [Medline].
5. Hodgkinson DJ, Hait G. Aesthetic vaginal labioplasty. *Plast Reconstr Surg*. Sep 1984;74(3):414-6. [Medline].
6. Alter GJ. A new technique for aesthetic labia minora reduction. *Ann Plast Surg*. Mar 1998;40(3):287-90. [Medline].
7. Choi HY, Kim KT. A new method for aesthetic reduction of labia minora (the deepithelialized reduction of labioplasty). *Plast Reconstr Surg*. Jan 2000;105(1):419-22; discussion 423-4. [Medline].
8. American Society of Aesthetic Plastic Surgeons. ASAPS 2013 Annual Statistics. ASAPS. Available at <http://www.surgery.org/media/news-releases/labiaplasty-and-buttock-augmentation-show-marked-increase-in-popularity>. Accessed 3/20/2014.
9. Rouzier R, Louis-Sylvestre C, Paniel BJ, Haddad B. Hypertrophy of labia minora: experience with 163 reductions. *Am J Obstet Gynecol*. Jan 2000;182(1 Pt 1):35-40. [Medline].
10. Koning M, Zeijlmans IA, Bouman TK, van der Lei B. Female attitudes regarding labia minora appearance and reduction with consideration of media influence. *Aesthet Surg J*. Jan-Feb 2009;29(1):65-71. [Medline].
11. Gress S. Composite reduction labiaplasty. *Aesthetic Plast Surg*. Aug 2013;37(4):674-83. [Medline].
12. Chang P, Salisbury MA, Narsete T, Buckspan R, Derrick D, Ersek RA. Vaginal labiaplasty: defense of the simple "clip and snip" and a new classification system. *Aesthetic Plast Surg*. Oct 2013;37(5):887-91. [Medline].
13. Davison SP, Baker CL, West JE. Labiaplasty and labia minora reduction. Medscape Reference. Available at <http://reference.medscape.com/article/1372175-overview>. Accessed February 28, 2014.
14. Trichot C, Thubert T, Faivre E, Fernandez H, Deffieux X. Surgical reduction of hypertrophy of the labia minora. *Int J Gynaecol Obstet*. Oct 2011;115(1):40-3. [Medline].
15. Iglesia CB, Yurteri-Kaplan L, Alinsod R. Female genital cosmetic surgery: a review of techniques and outcomes. *Int Urogynecol J*. Dec 2013;24(12):1997-2009. [Medline].
16. Alter GJ. Central wedge nymphectomy with a 90-degree Z-plasty for aesthetic reduction of the labia minora. *Plast Reconstr Surg*. Jun 2005;115(7):2144-5; author reply 2145. [Medline].
17. Kelishadi SS, Elston JB, Rao AJ, Tutela JP, Mizuguchi NN. Posterior wedge resection: a more aesthetic labiaplasty. *Aesthet Surg J*. Aug 1 2013;33(6):847-53. [Medline].

18. Hamori CA. Postoperative clitoral hood deformity after labiaplasty. *Aesthet Surg J*. Sep 1 2013;33(7):1030-6. [[Medline](#)].
19. Coleman S. Fat Augmentation of the Anterior Vaginal Wall: A Novel Use of Fat Augmentation in Enhancing the Female Sexual Experience. *Amer J Plast Surg*.
20. Goodman MP, Placik OJ, Benson RH 3rd, Miklos JR, Moore RD, Jason RA, et al. A large multicenter outcome study of female genital plastic surgery. *J Sex Med*. Apr 2010;7(4 Pt 1):1565-77. [[Medline](#)].
21. Davison SP, Labove G. Going in the wrong direction with monsoplasty. *Aesthet Surg J*. Nov 1 2013;33(8):1208-9. [[Medline](#)].
22. McPencow AM, Guess MK. Giving female genital cosmetic surgery a facelift. *Maturitas*. Apr 2012;71(4):313-4. [[Medline](#)].

Medscape Reference © 2011 WebMD, LLC