

Radiographic Implications of Fat Grafting to the Reconstructed Breast

Ximena A. Pinell-White, MD,* Joanna Etra, BA,* Mary Newell, MD,†
Daymen Tuscano, MD,† Kyungmin Shin, MD,† and Albert Losken, MD*

*Division of Plastic and Reconstructive Surgery, Emory University, Atlanta, Georgia; †Department of Radiology, Emory University, Atlanta, Georgia

■ **Abstract:** Autologous fat transfer is often used to smooth contour irregularities in the reconstructed breast. A potential concern with this technique is that it results in calcified lesions in the breast that can complicate subsequent cancer surveillance. The purpose of this review was to determine how fat grafting to the reconstructed breast impacts postoperative breast imaging. This is a matched cohort analysis of patients who underwent postmastectomy breast reconstruction with and without fat grafting as a secondary procedure. Nonfat grafted reconstructive patients were matched based on age, year of initial reconstruction, and type of reconstruction. Postoperative imaging at our institution was required for inclusion. The two groups were compared in terms of incidence and distribution of radiographic studies performed in follow-up and the need for biopsies. Fifty-one reconstructed breasts with a history of fat grafting were compared to 51 nonfat grafted, reconstructed breasts. The fat grafted group underwent a total of 204 breast imaging studies over a mean follow-up of 4.2 years, while the nonfat grafted group underwent 167 studies over 4.1 years ($p = 0.21$). More mammograms, ultrasounds, and magnetic resonance images were performed after fat grafting, but a significant difference was evident only for mammography (34 versus 12, $p = 0.05$). The incidence of breast biopsy to clarify abnormal imaging was nonsignificantly higher in the fat grafted group (17.6% versus 7.8%, $p = 0.14$). Fewer than 10 percent of imaging studies in the fat grafted cohort were performed to investigate a clinical or radiographic abnormality occupying the same breast quadrant as prior fat injection. Breast cancer patients treated with fat grafting required more breast imaging and biopsies than their nonfat grafted counterparts, but the areas of suspicion poorly corresponded to the site of prior fat grafting. Multimodal breast reconstruction may drive the additional diagnostic burden and not the fat grafting technique itself. ■

Key Words: autologous fat transfer, breast imaging, breast reconstruction, mammography

Autologous fat transfer is a common technique used to smooth contour irregularities that develop after aesthetic or reconstructive breast surgery and can be very effective in restoring a natural breast appearance (1). Across several clinical series investigating this technique, surgeons were satisfied with the results between 79 and 100 percent of the time, and judged superior results in 13 to 87 percent of cases (2). Patient satisfaction with the procedure was also generally high, with positive outcomes reported by 80 to 100 percent of patients.

These results hinge upon successful engraftment of the transferred fat, which in turn requires revascularization of the transplanted adipocytes in the recipient

bed. Failure of this process can result not only in resorption of the graft but also in fat necrosis, scarring, and calcification. This can produce nodularity of the breast and radiographic abnormalities, both of which can raise concern for cancer recurrence. A large systematic review of 17 studies on this topic found radiographic abnormalities in 13 percent of patients who had undergone fat grafting to the breast (3). These were predominantly cystic lesions, but nodules and microcalcifications that can mimic a cancer were also observed. The fundamental concern for some is that these abnormalities will impede the ability of breast radiologists to detect a malignancy. After some initial apprehension, autologous fat transfer has now been shown to be generally safe and its radiographic sequelae distinguishable from potentially cancerous lesions in most cases (4–7). Nevertheless, the clinical experience of patients who have undergone autologous fat transfer to the breast continues to be defined. The purpose of this review was to describe the need

Address correspondence and reprint requests to: Albert Losken, MD, Division of Plastic and Reconstructive Surgery, Emory University, 550 Peachtree Street, Suite 9000, Atlanta, GA 30308, USA, or e-mail: alosken@emory.edu

DOI: 10.1111/tbj.12450

© 2015 Wiley Periodicals, Inc., 1075-122X/15
The Breast Journal, Volume 21 Number 5, 2015 520–525

for follow-up imaging and biopsy in this population, and to examine the correspondence of clinical and radiographic abnormalities to the site of fat grafting.

MATERIALS AND METHODS

Study Population

Data were queried from a prospectively maintained data base of postmastectomy breast reconstructions performed at Emory University Hospital between 2007 and 2012. A matched cohort study was performed. All patients who underwent autologous fat transfer to the breast as an adjunct to postmastectomy breast reconstruction *and* had postoperative breast imaging performed at Emory were identified. An equal number of nonfat grafted reconstructive patients who also had postoperative imaging performed at Emory were matched based on age at initial reconstruction (± 5 years), year of initial reconstruction (± 2 years), and type of reconstruction (implant based, transverse rectus abdominis musculocutaneous flap, or latissimus dorsi flap with or without implant). Prophylactic mastectomies were included, such that some patients were at high risk for breast cancer but had no personal history. All reconstructive techniques were permitted.

The two groups were compared in terms of several clinical variables, including the incidence of radiation therapy and the total number of surgeries performed on the reconstructed breast. Both oncologic (including prior lumpectomies) and reconstructive procedures (including fat grafting) were included in this count. The total number and distribution of radiographic studies over a similar interval of follow-up were compared between the fat grafted and nonfat grafted groups. The imaging modalities considered were mammography, breast ultrasound (US) and magnetic resonance imaging (MRI), and chest computed tomography (CT) or combined positron emission tomography (PET)-CT. While CT and combined PET-CT were not dedicated breast imaging, we included this modality to determine if any abnormalities potentially attributable to fat transfer were detected on CT. The prevalence of abnormal imaging was compared between the two cohorts on a per patient basis. For this purpose, an abnormality was defined as anything other than normal breast tissue or an expected postoperative change. Abnormalities did not necessarily suggest malignancy, as in the case of fat necrosis or oil cysts. A chest CT or PET was deemed abnormal in

this context if it demonstrated an abnormality in the breast. The incidence of breast biopsies necessitated by indeterminate imaging was also compared. Finally, abnormal clinical or radiographic findings that necessitated additional diagnostic studies in the fat grafted cohort were reviewed to determine concordance with the site of prior fat infiltration. This was liberally defined, with any lesion visualized in the same breast quadrant counting as corresponding to the fat injection.

Statistics

A paired samples *t*-test was used to compare the number of radiographic studies in the fat grafted and nonfat grafted groups, and a chi-squared or Fisher's exact test was used to compare categorical variables between the two (e.g., incidence of biopsies). A *p*-value less than 0.05 was considered statistically significant in all cases.

RESULTS

Forty-six patients underwent fat grafting to a total of 51 breasts treated previously with mastectomy and reconstruction and had sufficient data for inclusion in this study. Fifty-one patients that had undergone postmastectomy breast reconstructions *without* subsequent fat grafting were also identified. All patients had postoperative breast imaging performed at our institution. The two groups were well matched in terms of age, interval since initial reconstructive surgery, and distribution of reconstructions (Table 1). Most had under-

Table 1. Patient Characteristics

	Fat grafted (N = 51)	Not fat grafted (N = 51)	p-value
Age, mean (range)	49.6 years (32–68)	48.9 years (32–66)	0.69
Follow-up, mean (range)	4.2 years (1.6–8.9)	4.1 years (1.1–7.3)	0.74
Reconstruction			
Tissue expander/implant	12 (23.5%)	12 (23.5%)	
LDF only	4 (7.8%)	4 (7.8%)	
LDF + tissue expander	18 (35.3%)	18 (35.3%)	
TRAM	17 (33.3%)	17 (33.3%)	1.00
Number of surgeries to reconstructed breast, mean (range)	3.57 (2–7)	2.82 (1–5)	0.002
Radiation therapy	21 (41.2%)	26 (51%)	0.32

LDF, latissimus dorsi flap; TRAM, transverse rectus abdominis musculocutaneous flap.

gone immediate breast reconstruction following mastectomy (94% of fat grafted patients, 92% nonfat grafted patients). Forty-one percent of fat grafted patients and 51% of nonfat grafted patients received radiation to the reconstructed breast, and in some cases to the supraclavicular fossa as well ($p = 0.32$). The period reviewed spanned an average of 4 years after reconstruction for both cohorts. For the fat grafted cohort, the fat transfer procedure occurred at a mean of 1.3 years (range 0.2–5.8) after the initial reconstruction. On average, the fat grafted group underwent almost one additional surgery to the reconstructed breast (3.57 versus 2.82, $p = 0.002$).

In the fat grafted group, the average volume of lipoinfiltrate at the initial operation was 29 mL (range 10–90). Ten patients underwent a second fat grafting procedure, which brought the mean cumulative volume to 36.3 mL. The fat transfer was most often directed to the upper pole ($n = 32$, 62.7%), followed by the medial breast ($n = 5$, 9.8%), a combination ($n = 5$, 9.8%), or one of various other sites ($n = 9$, 17.9%).

At a mean follow-up of just over 4 years, the fat grafted group collectively underwent 22 percent more imaging studies than their nonfat grafted counterparts (204 versus 167, $p = 0.21$, Fig. 1). The fat grafted group had more mammograms, breast USs, and breast MRIs performed, but this achieved significance only for mammograms (34 versus 12, $p = 0.05$). Patients who had not been fat grafted had a slight but nonsignificant excess of chest CTs and PET scans.

The number of studies performed in each cohort was also examined by indication. The fat grafted cohort required more breast imaging studies to investi-

gate new clinical findings, such as a mass (45 versus 28, $p = 0.14$). Their surveillance studies also generated more patient recalls and more additional studies to clarify indeterminate findings (10 versus 4, $p = 0.31$). The remainder of excess studies in the fat grafted cohort arose from a greater number of breast cancer screening studies performed in that group (149 versus 135, $p = 0.57$).

Although more studies were needed to evaluate the fat grafted breasts, the prevalence of abnormal imaging per patient was not statistically different between the two groups (Table 2). Overall, fat grafted patients more often had abnormal radiographic imaging, but this did not reach statistical significance (43.1% of all studies versus 29.4%, $p = 0.15$). The average volume of fat transferred was no different among patients with subsequently abnormal breast imaging and those with normal studies (35.2 versus 36.9 mL, $p = 0.82$).

The incidence of biopsies obtained to clarify radiographic anomalies was more than twice as high in fat grafted breasts though not statistically significant (17.6% versus 7.8%, $p = 0.14$). Four residual or recurrent cancers were identified in the nonfat grafted group (100% of all patients who received biopsies), compared to three cancers diagnosed in the fat grafted group (33.3% of all patients biopsied).

In the fat grafted group, 17 breasts were imaged for a clinical finding in the breast, the most common of which was a palpable mass ($n = 12$, 70.6%). Multiple modalities were often required to characterize these lesions, such that 45 additional studies were performed, most of which were USs ($n = 24$) and mammograms ($n = 16$). Twelve studies were performed in four patients who developed suspicious clinical findings *before* they had undergone fat grafting. Of the remaining 33 studies performed for clinical findings postfat grafting, 18 studies (54.5%) of seven breasts corresponded to the site of fat infiltration, and 15 studies (45.5%) in six breasts did not.

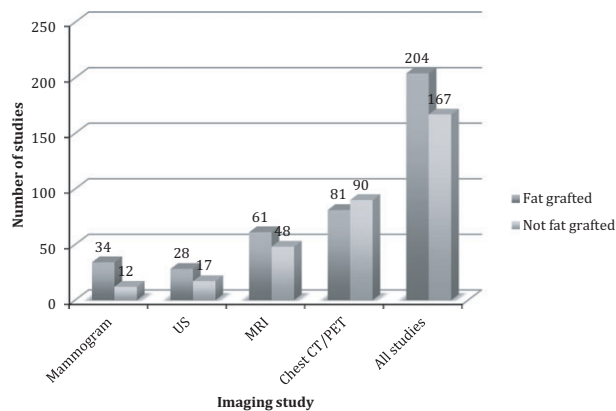


Figure 1. Collective number of studies in fat grafted versus nonfat grafted cohorts.

Table 2. Prevalence of Abnormal Imaging by Radiographic Modality

	Fat grafted	Not fat grafted	p-value
Mammogram	6/17 (35.3%)	5/9 (55.6%)	0.42
US	11/17 (64.7%)	7/13 (53.8%)	0.55
MRI	11/28 (39.3%)	5/23 (21.7%)	0.18
PET/CT	5/35 (14.3%)	8/35 (22.9%)	0.36
Any study	22/51 (43.1%)	15/51 (29.4%)	0.15

US, ultrasound; MRI, magnetic resonance image; PET, positron emission tomography; CT, computed tomography.

Six patients in the fat grafted cohort (11.8%) were recalled for an abnormal finding on screening mammography or MRI and collectively underwent an additional 10 studies. One patient recall and three studies predated the fat grafting procedure. Of the remaining five patients, only in one case (and one imaging study, 20%) did the radiographic abnormality correspond to the site of prior fat transfer.

Overall, less than 10 percent of imaging studies in the fat grafted cohort were performed in the investigation of a clinical or radiographic abnormality potentially attributable to the fat grafting procedure (Fig. 2).

Among the nine biopsies performed to diagnose lesions demonstrated on imaging in the fat grafted cohort, three occurred prior to the fat grafting procedure. Only two of the remaining six addressed a lesion occupying the same breast quadrant as the prior breast imaging procedure—one fat necrosis, the other a recurrent cancer.

DISCUSSION

As autologous fat transfer is increasingly performed as an adjunct to postmastectomy breast reconstruction, it is important that reconstructive surgeons understand the radiographic implications of this technique and appropriately counsel patients. It is equally important that other members of the oncological team and radiologists familiarize themselves with the various reconstructive techniques and how they can affect surveillance. The incidence of radiographic abnormalities following fat grafting to the breast varies widely in the literature, ranging from 0 to 86 percent (3). In this study, our objective was not to quantitate rates of abnormal imaging at our institution, but rather to describe the clinical experience of patients who have undergone fat grafting, insofar as the need for diag-

nostic imaging and further investigate of indeterminate findings.

We found that women who had undergone fat grafting to revise a reconstructed breast required 20 percent more imaging studies and twice as many breast biopsies than their nonfat grafted counterparts, though these comparisons did not achieve statistical significance. However, the additional diagnostic burden, defined as those studies *not* performed for routine cancer surveillance, was potentially attributable to the fat grafting procedure in only one-third of cases. Most palpable masses or radiographic anomalies requiring patient recall were either distant from the site of fat infiltration or developed before fat grafting was even performed.

The excess of radiographic studies in the fat grafted cohort may be related to the condition of the difficult, multiply reoperated breast in which fat grafting is employed, and not to the fat grafting technique itself. The fat grafted cohort underwent on average 3.6 surgeries to the reconstructed breast, compared to 2.8 procedures in the nonfat grafted group ($p = 0.002$). The added surgery conceivably introduces additional parenchymal scarring that is perceived by the patient or clinician as a mass or that obscures screening efforts. Alternatively, the reconstructed breast treated with autologous fat transfer may inherently have more areas of fibrosis, as these are often responsible for the irregularities that fat grafting seeks to correct.

The prevalence of abnormal imaging in this study was nonsignificantly higher in the fat grafted cohort, 43 versus 29 percent ($p = 0.15$), though both figures are considerably higher than other series on breast imaging in fat grafted patients. In a systematic review of fat transfer to the breast by Claro et al., the rate of abnormal breast imaging across 17 studies was 13 percent, though with wide variability among individual studies (3). Among possible explanations for their lower rate of radiographic abnormalities are the average follow-up of only 1 year, inclusion of aesthetic patients, unknown mix of mammography, US, and MRI, and unspecified definition of abnormal imaging. In our study, radiographic abnormalities included any apparent lesion, even if it could be characterized as benign, such as an oil cyst. With this expansive definition, the rate of abnormality can be expected to be higher. Moreover, in our series, more than a quarter of studies were performed in the investigate of a clinical or radiographic finding, where the probability of an abnormality was greater from the outset.

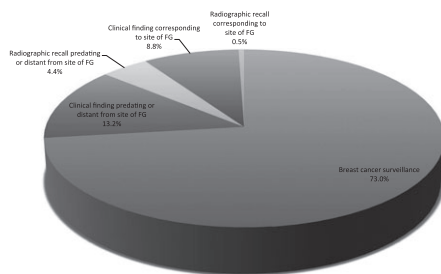


Figure 2. Imaging indications in fat grafted cohort. FG: fat grafting.

While we note that the incidence of biopsy-proven cancer recurrences identified in these two groups is similar—three in the fat grafted cohort versus four in the nonfat grafted cohort, the oncologic safety of fat transfer to the breast is beyond the objectives and scope of this study. As adipocytes and their progenitor cells can stimulate angiogenesis and cellular proliferation (8), fat grafting in the breast cancer patient has been a topic of great controversy. A case-control study published in 2012 compared 321 patients treated with partial or total mastectomy followed by autologous fat transfer to 642 nonfat grafted controls matched by age, year of surgery, oncologic procedure, and tumor histology (9). At a mean follow-up of 56 months after oncologic surgery, the rate of local-regional recurrence was no different between the fat grafted and nonfat grafted groups (hazard ratio 1.11, 95% confidence interval 0.47–2.64, $p = 0.792$), except when the analysis was confined to a small subset of *in situ* tumors. Fat transfer to the breast appears to be oncologically safe, though prospective trials with long-term follow-up are necessary to confirm this.

As fat grafting becomes increasingly utilized in breast cancer patients, numerous papers have recently discussed the radiographic implications of this procedure. The most common finding on mammography of the fat grafted breast is scattered microcalcifications (4), which generally mandate additional imaging to distinguish them from a possible cancer. Multiple imaging modalities are frequently needed to reliably diagnose the sequelae of fat grafting. US has been described as more sensitive for normal findings, such as oil cysts, while MRI more accurately distinguishes fat necrosis from a possible malignancy (5). A recently published study by Parikh et al. proposes a standardized classification system to describe fat grafted breasts using characteristic features on US (10). Typical findings in fat necrosis, such as circumscribed margins and avascularity, allow diagnoses to be made on the basis of imaging, and avoid unnecessary biopsies.

Veber et al. found a high incidence of mammographic abnormalities in a small series of patients who were augmented with fat transfer (7). The incidence approached 50%, the most common of which were fatty cysts and microcalcifications. However, when comparing pre- and postfat transfer mammograms, they found no difference in breast density or American College of Radiology Breast Imaging Reporting and

Data System II (BI-RADS) classification, with all patients effectively categorized as a BI-RADS 1 or 2 after surgery. The authors conclude that while fat grafting may introduce radiographic abnormalities, these can be accurately distinguished from potentially malignant lesions by the experienced radiologist. Although some authors have raised concerns about the potential interference with breast cancer surveillance (11), this has not necessarily been demonstrated in the literature. Any surgical procedure, whether a breast reduction, augmentation, or lipotransfer, has the potential for additional scarring and subsequently a higher incidence of mammographic abnormality. It is, however, up to the multi-disciplinary team involved in the patient's care to better identify these findings as benign and minimize the need for tissue sampling. Communication between the radiologist and the surgeon is important to interpret imaging findings in the context of the surgical intervention. Doren et al. has proposed an algorithm based on location of fat grafting, BI-RADS scoring system, and potentially an US for higher risk patients to differentiate fat necrosis following fat grafting from tumor recurrence (12). Our multi-disciplinary research team plans to expand upon our current research efforts to develop and prospectively study a diagnostic algorithm in this population.

We acknowledge certain limitations to this study, namely the retrospective nature of data collection and modest sample size that limits our ability to make statistical inferences. Because screening practices following mastectomy are not uniform, our comparator group was a reconstructive cohort matched on the basis of select variables, which could be incomplete and a source of confounding.

CONCLUSIONS

Breast cancer patients treated with multimodal breast reconstruction that included fat grafting required more breast imaging and biopsies than their nonfat grafted counterparts. The areas of suspicion poorly corresponded to the site of prior fat grafting, suggesting that the difficult, reoperative breast in which fat grafting is utilized may drive the additional diagnostic burden and not the fat grafting technique itself. It is important that all members of the breast oncology team be aware of the various reconstructive options and how they potentially impact postoperative cancer surveillance.

REFERENCES

1. Losken A, Pinell XA, Sikoro K, *et al.* Autologous fat grafting in secondary breast reconstruction. *Ann Plast Surg* 2011;66:518–22.
2. Chan CW, McCulley SJ, Macmillan RD. Autologous fat transfer—a review of the literature with a focus on breast cancer surgery. *J Plast Reconstr Aesthet Surg* 2008;61:1438–48.
3. Claro F Jr, Figueiredo JC, Zampar AG, *et al.* Applicability and safety of autologous fat for reconstruction of the breast. *Br J Surg* 2012;99:768–80.
4. Carvajal J, Patiño JH. Mammographic findings after breast augmentation with autologous fat injection. *Aesthet Surg J* 2008;28:153–62.
5. Costantini M, Cipriani A, Belli P, *et al.* Radiological findings in mammary autologous fat injections: a multi-technique evaluation. *Clin Radiol* 2013;68:27–33.
6. Pierrefeu-Lagrange AC, Delay E, Guerin N, Chekaroua K, Delaporte T. Radiological evaluation of breasts reconstructed with lipomodelling. *Ann Chir Plast Esthet* 2006;51:18–28.
7. Veber M, Tourasse C, Toussoun G, *et al.* Radiographic findings after breast augmentation by autologous fat transfer. *Plast Reconstr Surg* 2011;127:1289–99.
8. Lohsiriwat V, Curigliano G, Rietjens M, *et al.* Autologous fat transplantation in patients with breast cancer: “silencing” or “fueling” cancer recurrence? *Breast* 2011;20:351–7.
9. Petit JY, Botteri E, Lohsiriwat V, *et al.* Locoregional recurrence risk after lipofilling in breast cancer patients. *Ann Oncol* 2012;23:582–8.
10. Parikh RP, Doren EL, Mooney B, *et al.* Differentiating fat necrosis from recurrent malignancy in fat-grafted breasts: an imaging classification system to guide management. *Plast Reconstr Surg* 2012;130:761–72.
11. Wang CF, Zhou Z, Yan YJ, *et al.* Clinical analyses of clustered microcalcifications after autologous fat injection for breast augmentation. *Plast Reconstr Surg* 2011;127:1669–73.
12. Doren EL, Parikh RP, Laronga C, *et al.* Sequelae of fat grafting postmastectomy: an algorithm for management of fat necrosis. *Eplasty* 2012;12:e53.