

# Simultaneous Breast Augmentation with Periareolar Mastopexy

Steven P. Davison, M.D., D.D.S., F.A.C.S.<sup>1</sup> and Scott L. Spear, M.D., F.A.C.S.<sup>1</sup>

## ABSTRACT

Augmentation mammoplasty is frequently used to fill out the soft tissue envelope of the breast. This is most successful with minimal skin laxity or when there is no need for significant nipple movement. The addition of a periareolar mastopexy can reduce the skin envelope; however, its value is limited to those with no more than mild second-degree ptosis. Although this is a valuable technique, the risks involved with the operation are additive, and, accordingly, patient selection and surgical technique is important.

**KEYWORDS:** Augmentation, periareolar mastopexy, breast ptosis, mastopexy, breast lift

Augmentation of the breast with simultaneous mastopexy is not a new concept. However, recent modifications and insights into this complex operation warrant inclusion in *Seminars in Plastic Surgery*.

As early as 1960, Gonzales-Ulloa described the correction of the hypoplastic ptotic breast by combining alloplastic augmentation and mastopexy, signifying that this concept clearly is not new.<sup>1</sup> However, increasing awareness of the complexities of adding an implant to fill out the associated volume of the breast while reducing the skin envelope makes this specific subject particularly timely for discussion in *Seminars in Plastic Surgery*.<sup>2</sup> The utilization of a modified donut mastopexy for the skin excision around the areolar can minimize the extent of the scar.<sup>3</sup> Careful positioning of the implant in either a subglandular or a partially subglandular subpectoral pocket<sup>4</sup> and the addition of techniques from Benelli that include the blocking or purse-string closure of the associated periareolar incision<sup>3</sup> are more modern concepts that can facilitate the procedure.

The goals of augmentation with simultaneous mastopexy have been described by Persoff to include:

(1) elevation of the mound; (2) elevation of the nipple-areolar complex; (3) conversion from a ptotic breast to a conical breast; (4) enlargement of volume; and (5) improved breast symmetry.<sup>2</sup> A key challenge is to remove enough skin with the mastopexy to create an appropriately tight brassiere, yet leave enough laxity within the soft tissue envelope for the increased volume from the implant.

Although mastopexy alone is a purely elective procedure, mastopexy with augmentation may be necessary to avoid an unattractive augmented breast.

## BREAST PTOSIS

Breast ptosis is indicated by one or more of the following: nipple descent on the chest in relation to the inframammary fold, breast descent on the chest, or nipple descent in relation to the breast. Regnault's classification of ptosis is not significantly comprehensive because it focuses primarily on nipple position on the chest, rather than describing the nipple relationship to the gland and the associated glandular position on the

New Trends in Reduction and Mastopexy; Editor in Chief, Saleh M. Shenaq, M.D.; Guest Editors, Scott L. Spear, M.D., F.A.C.S. and Steven P. Davison, M.D., D.D.S., F.A.C.S. *Seminars in Plastic Surgery*, Volume 18, Number 3, 2004. Address for correspondence and reprint requests: Scott L. Spear, M.D., F.A.C.S., Georgetown University Hospital, 3800 Reservoir Road, Washington, DC 20007. <sup>1</sup>Georgetown University Hospital, Washington, DC. Copyright © 2004 by Thieme Medical Publishers, Inc., 333 Seventh Avenue, New York, NY 10001 USA. Tel: +1(212) 584-4662. 1535-2188,p;2004,18,03,189,201,ftx,en;sps00126x.

chest.<sup>4</sup> Regnault's currently accepted classification is as follows:

*Glandular ptosis:* The nipple is above the fold, but the breast hangs below the fold.

*Grade I or minor:* The nipple is at or near the level of the inframammary fold.

*Grade II or moderate:* The nipple is below the inframammary fold but above the lower breast contour.

*Grade III or severe:* The nipple is at the lower breast contour and below the inframammary fold.

An additional classification includes *pseudoptosis*: The nipple is above the fold, but the breast is hypoplastic and hangs below the fold (which seems virtually the same as glandular ptosis).

In the complete examination of breast ptosis, one needs to observe the degree of nipple ptosis, the degree of breast ptosis, the quality and quantity of the associated breast tissue, and the volume of the soft tissue envelope. Although a patient with a nipple at the inframammary fold with either 1 to 2 cm or 5 cm of breast below the fold would still be graded at first-degree ptosis, the challenges to achieve a successful cosmetic augmentation in either case with or without mastopexy would clearly be very different. The 5 cm of breast below the fold would significantly increase the difficulty.

The more gland or skin that overhangs the fold, the more inadequately the implant will fill out the breast without adjusting the skin envelope. An implant alone will not shift the nipple superiorly enough for the breast to achieve an aesthetic, acceptable result. The ptotic small breast may need only an implant, the fold lowered, or minimal nipple elevation and skin excision. The ptotic large breast may need a larger implant or more aggressive skin resection but not lowering of the associated fold. As early as 1979, Owsley described the simultaneous mastopexy and augmentation for correction of the small, ptotic breast.<sup>5</sup> However, his technique used a modified Aries-Pitanquy mastopexy pattern with associated T-type incisions.

### DONUT MASTOPEXY

In 1980, Gruber and Jones presented the donut mastopexy with its indications and associated complications.<sup>6</sup> They discussed the drawback with an associated mastopexy as an associated scar. Therefore, they confined the mastopexy to the periareolar region, limiting the skin excision to 2 to 3 cm in radius. In their original article they also discussed combining mastopexy with augmentation mammoplasty. Gruber described the de-epithelization of the associated skin with double-layer closure with absorbable sutures, as well as some problems with hypertrophy and spread of the periareolar incision. In 1985, Puckett and colleagues described a crescentic

mastopexy association.<sup>7</sup> They performed simultaneous mastopexy and augmentation on 26 patients using a crescentic mastopexy with a potential ability to lift the nipple 1.5 to 2 cm. They described the utilization in patients with nipple below the associated fold who needed more than augmentation, calling this one-and-a-half-grade ptosis. Their closure was a continuous subcuticular monofilament nylon, which they left in place for 3 weeks. However, they experienced a 46% complication rate (12 patients) with scar widening by more than 5 mm or a change to an oval areolar pattern.

### BLOCKING SUTURE

In 1992, two significant contributions to the periareolar mastopexy enhanced our understanding and acceptance of this technique. The first of these was the mathematical approach to the skin resection described by the senior author Spear and was based on two principles: First, the outside diameter of the excision must not be drawn to exceed the original areolar diameter by more than the original areolar diameter exceeds the inner concentric circular diameter; and second, the outer circle diameter must not be drawn to exceed twice the inner circle.<sup>8</sup> These principles were applied to prevent scarring or overflattening of the associated breast.

The second contribution was Benelli's "round block" technique, also known as the blocking suture.<sup>3</sup> This technique has been extrapolated and the periareolar mastopexy emphasized a circular nonabsorbable suture around the periareolar circular dermoepithelial incision. The goal of this technique is to limit the scar around the areola, resulting in a fundamental improvement in the associated technique for the periareolar mastopexy.

The authors currently use a 3.0 Mersilene (Ethicon, Sumerville, NJ) or 2.0 Goretex (W. L. Gore, Phoenix, AZ) on a long straight needle for the blocking suture. This decreases the risk of enlargement of the areola by using a permanent suture. The straight needle decreases the likelihood and degree of periareolar puckering. The actual stitch is not placed in the dermis skin edge but ~0.5 cm closer to the nipple to reduce puckering.

### DIFFICULT EXECUTION

The conflicting goals of mastopexy and breast augmentation, one that reduces the soft tissue envelope and one that fills it up, set the stage for additional risks in that the operation includes all the individual risks of breast augmentation and mastopexy and magnifies them.<sup>9,10</sup> These include (1) increased risk of implant infection with either an exposure or malposition; (2) increased risk of nipple or flap necrosis; (3) uncertainty about nipple-to-breast and implant relationships with potentially worse scars and decreased nipple sensation; and (4)

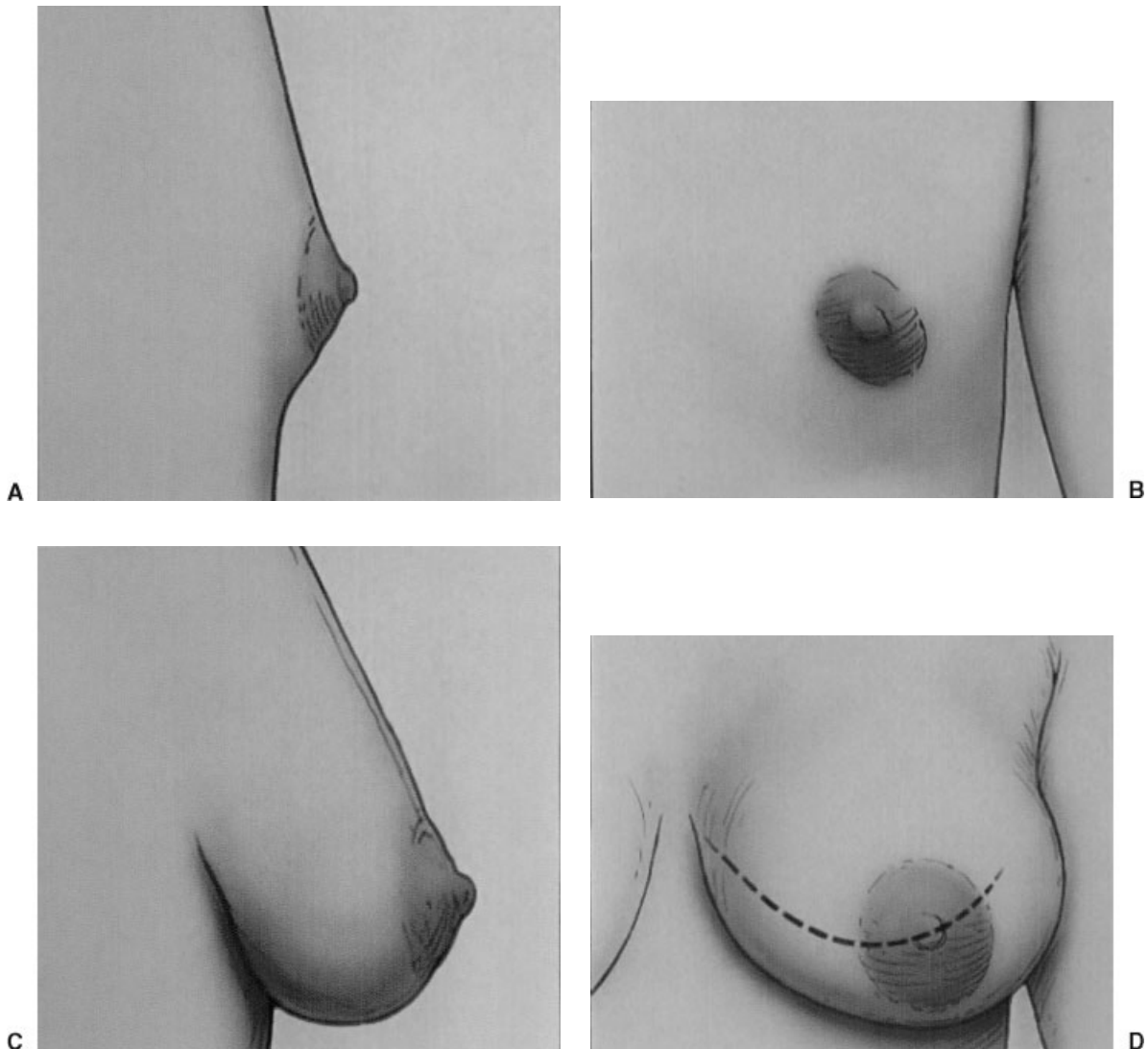
relapse of the associated ptosis. Relapse of the associated ptosis and spreading of the areolar scars can be addressed to some extent by converting the periareolar mastopexy to a vertical or inverted T-scar procedure.<sup>9</sup> The variability of factors in decision making and execution makes a simple algorithm difficult. In addition, the factors leading to the original need for an augmentation mastopexy, including aging changes, breast ptosis, and skin laxity, are progressive. A recent review by Spear and associates indicated that 50% of his augmentation/mastopexy practice was revision of previous operations.<sup>11</sup> With such a high recidivism rate, surgeons need to plan for obsolescence and perform a procedure that allows a secondary operation in the future. The indications for revision operation in his series were capsular contracture, nipple or breast ptosis, implant malposition, size dissatisfaction, or poor scarring. The majority of the mastopexy revisions had a revision of recurrent or

undercorrected ptosis. In revision mastopexies, 90% of the patients did not require change in the type of mastopexy and if they did, the revision moved to the next echelon of technique, such as the addition of a vertical limb to the periareolar mastopexy scar. This potential need for revision suggests that there needs to be consistency of access incision for implant position and a thorough discussion in the medical record of the associated incisions and pedicles.

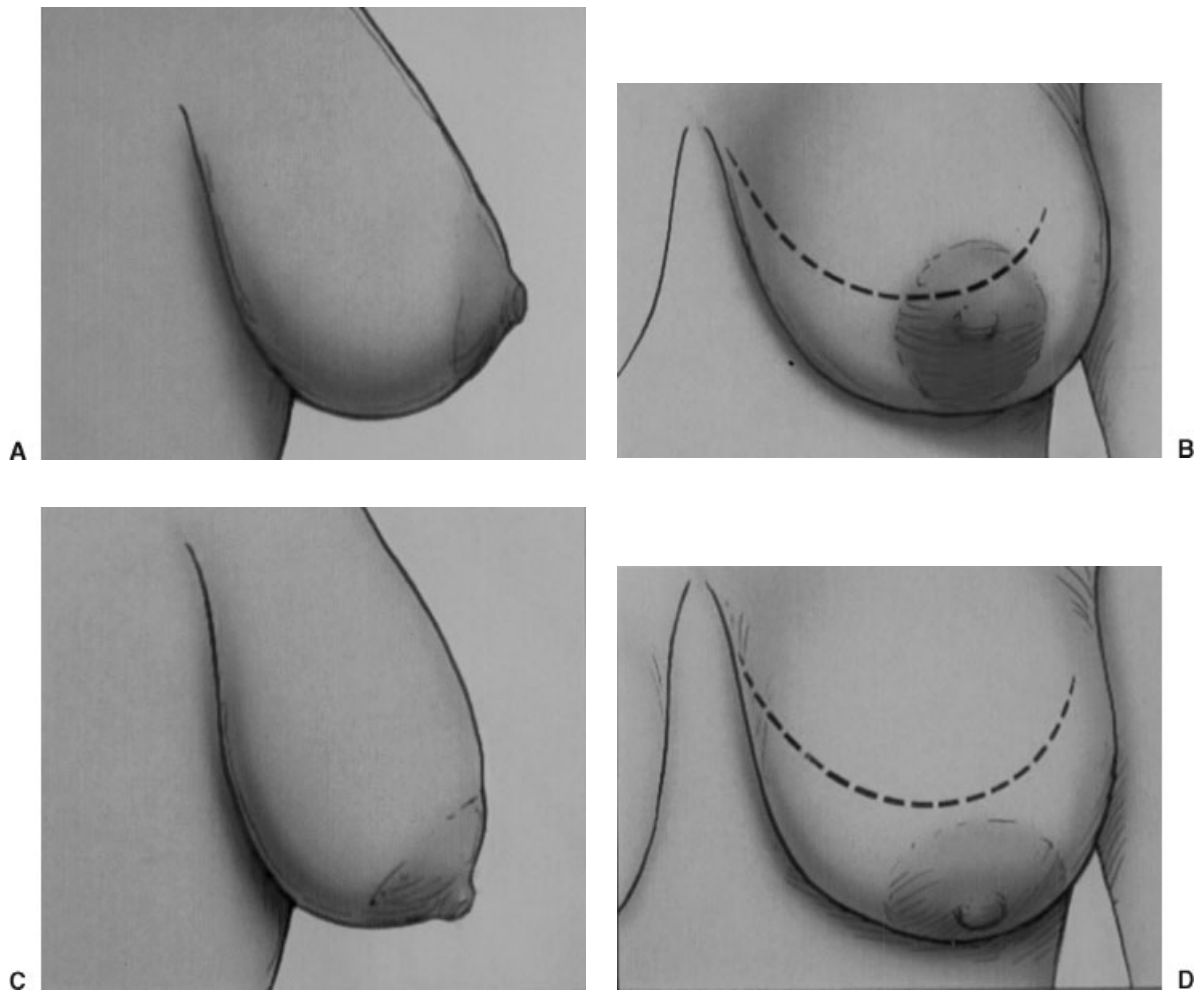
### BASIC PRINCIPLES

Mastopexy may not be required with breast augmentation when the nipple is at or above the fold or the nipple-areola is above the lower breast border and there is 2 cm or less of breast ptosis (Fig. 1).

Reasonable indications for periareolar mastopexy with breast augmentation include (1) nipple near or no



**Figure 1** (A–D) Mastopexy may not be required with breast augmentation when the nipple is at or above the fold, or the nipple-areola is above the lower breast border and there is 2 cm or less of breast ptosis.



**Figure 2** (A–D) Reasonable indications for periareolar mastopexy with breast augmentation include nipple near or no more than 2 cm below the fold, nipple-areola no lower than the breast border and pointing inferiorly, and no more than 3 to 4 cm of associated breast ptosis.

more than 2 cm below the fold, (2) nipple-areola no lower than the breast border and not pointing inferiorly, or (3) no more than 3 to 4 cm of associated breast ptosis (Fig. 2).<sup>12,13</sup>

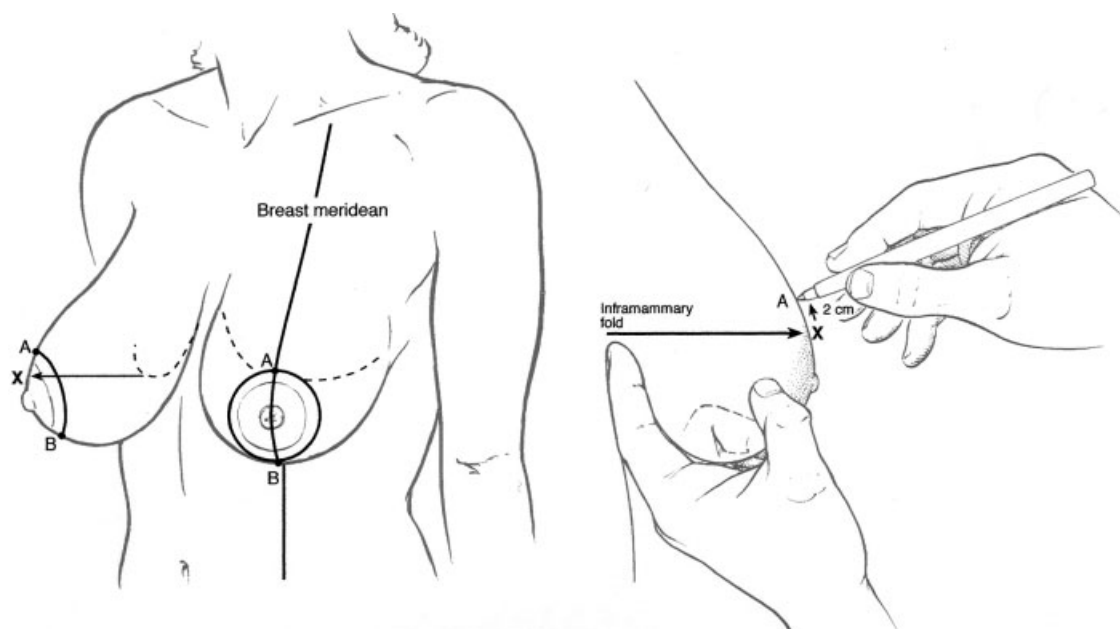
### PLANNING AND MARKING

The patient is positioned upright with arms at the sides. The midline of the chest and the inframammary fold are marked with indelible marker. The meridian of each breast is marked with a line dropped from the midclavicle to the inframammary fold. The marked meridian is used to help locate the ideal new position of the nipple as opposed to the nipple being used to define the correct position of the meridian. Thus, this technique can be used to address some degree of asymmetry.<sup>12</sup>

Setting the nipple height is extremely important. The position is determined by multiple factors. The distance from the sternal notch to the nipple should be in a range of 19 to 25 cm. It is influenced by height,

breast, and body habitus. The nipple height should be at or up to 6 to 8 cm above the inframammary fold at the apex of the anticipated breast mount. The nipple should not be placed too high during augmentation/mastopexy because it looks unnatural and is difficult to fix, particularly if implants drop. However, in distinction to a breast reduction, it is also a mistake to place the nipple too low. Bear in mind the difference between breast reduction and augmentation/mastopexy. In the case of the former, the enlarged breast typically descends below the fold in concert with the nipple. In augmentation/mastopexy, the preoperative nipple may already be at or near the fold, but the augmented breast in most cases will ultimately sit well above the fold, thus requiring a higher nipple position.

The new nipple position is marked by an “X” (Fig. 3). After nipple position is marked, the planned upper margin of the areola “A” is marked. This is drawn 2 cm higher than point “X.” The amount of skin to be left from the inferior edge to the inframammary fold is determined by the anticipated size of the augmented



**Figure 3** Marking of the patient. The inframammary fold and breast meridian are marked first (top). Point "X" represents the new nipple position. It is located at or slightly above the inframammary fold. Points "A" and "B" mark the extent of skin excision. Point "A" is 2 cm superior to point "X" (bottom).

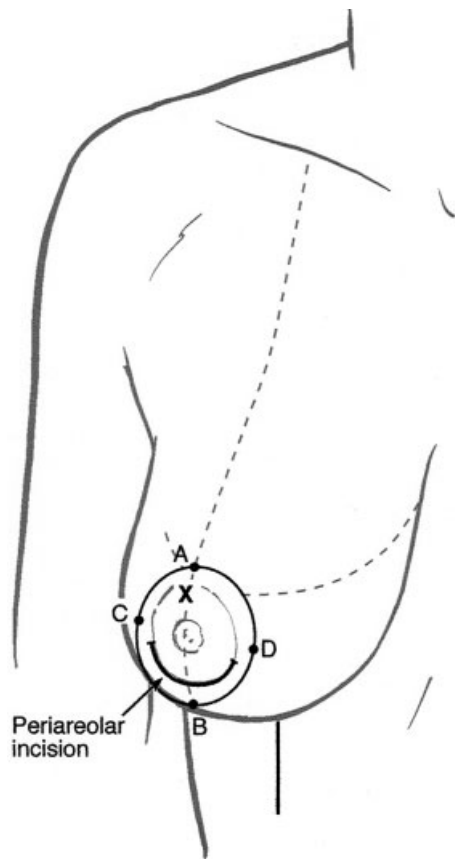
breast, not by a fixed formula. Large breasts may require up to 7 cm of inferior skin; small breasts, 5 cm of inferior skin. Point "B" marks the junction of the breast meridian between the skin that is left inferiorly and the skin to be removed beneath the areola. The amount of skin to leave medially, point "C," and laterally, point "D," is assessed and marked. The shape of the skin to be excised is typically not perfectly round and concentric but may be more oval and eccentric so as to lift the nipple and not overly narrow the width of the breast. More often than not, points "C" and "D" lie just outside the current areolar margins. The dimension of the horizontal axis of the circle is thus often significantly less than the vertical dimension. The size of the concurrent augmentation affects the size of the final design of the skin envelope, but typically point "C" is 8 to 12 cm from the chest midline. If no horizontal nipple repositioning is needed, point "D" is often more or less equidistant to the meridian as the meridian is from point "C." If medial lateral movement is needed, point "D" is moved appropriately and given an asymmetrical skin resection relative to the median. Asymmetrical excision of skin in the circumareolar mastopexy may be used to address cases of breast asymmetry as it adjusts and manages the skin envelope.<sup>12</sup>

### IMPLANT CHOICE

Thin, soft tissues do better with more skin reduction and silicone gel implants, rather than filling out loose skin with a large saline implant.

Anatomical implants may reduce the tendency of the excessive upper pole fullness above an already ptotic nipple and may mitigate the need for any mastopexy in mild cases. Augmenting the mild to moderately ptotic breast may remove the need or reduce the extent of a mastopexy; therefore, do not commit to the full mastopexy plan until the implant has been placed. The markings can be reassessed intraoperatively using the common method of "tailor-tacking." If there is any doubt, the mastopexy can be deferred until the second stage.

In present-day North America, most patients undergoing augmentation/mastopexy are primarily interested in augmentation; thus, foregoing or diminishing the extent of the mastopexy would be favorable. For other patients and in other cultures, the mastopexy may be primary; then, the mastopexy could be performed first, and an appropriate size implant (probably smaller) chosen afterward. The implant position is important. In the authors' opinion, volume restoration of the ptotic breast is best in either the subpectoral dual-plane position or subglandular position, which are cosmetically more or less equivalent. However, the authors believe the subpectoral dual-plane position may be better for mammography, capsular contracture, and implant palpability and visibility and should help minimize the devascularization of the breast. The authors believe total submuscular/subfascial positioning is contraindicated because it may accentuate glandular or nipple ptosis since the implant remains fixed over time while the breast gland and nipple inevitably descend some.



**Figure 4** The periareolar incision for the augmentation is made from 4 to 8 o'clock on the inferior margin of the areola. This hides the incision for the augmentation while maximizing surgical access if the mastopexy is not completed.

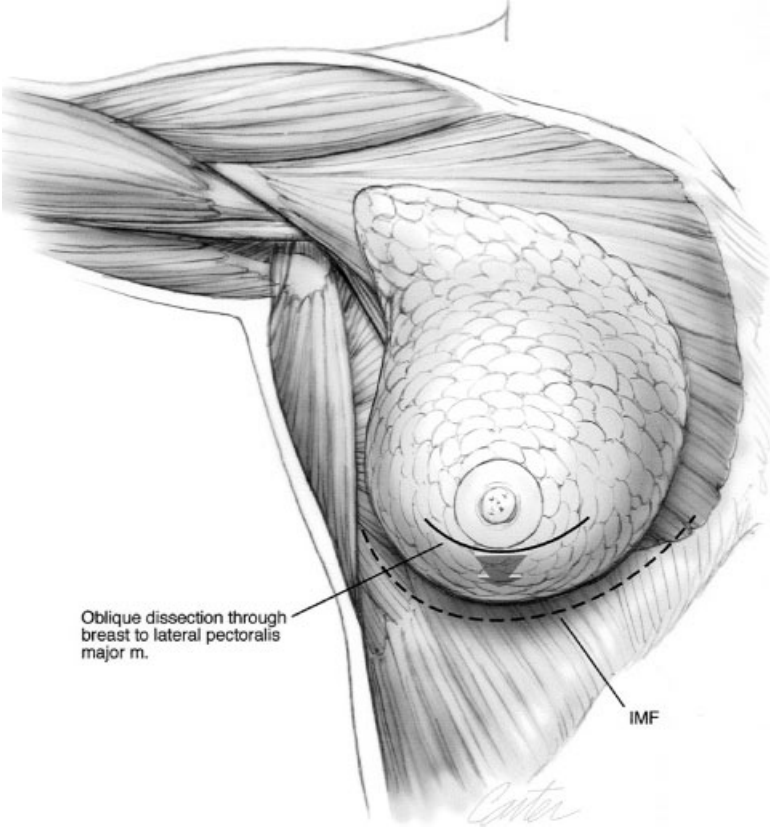
### OPERATIVE TECHNIQUE

A circle of 38 to 50 mm is first marked with a sterile marking pen within the boundary of the existing areola. The outer circle as marked preoperatively is also redrawn. Depending upon the circumstances, an incision can be made anywhere between these two circles. One may conservatively make a periareolar incision along the lower edge of the existing areola precisely along its edge (Fig. 4). Using electrocautery, an oblique dissection is carried through the breast parenchyma directed inferiorly toward the pectoralis muscle fascia. Great care is taken to ensure that the inferior flap is at least 1 cm thick. This ensures adequate soft tissue coverage over much of the inferior pole (Fig. 5). Surgical decision making is now dependent on whether the implant will be subglandular or partial subpectoral. Glandular placement requires that the available breast tissue be adequate to camouflage implant contour, particularly if using saline-filled implants. Although patients being considered for mastopexy will typically have some laxity, the better the skin quality, the more likely subglandular saline implants will prove satisfactory.

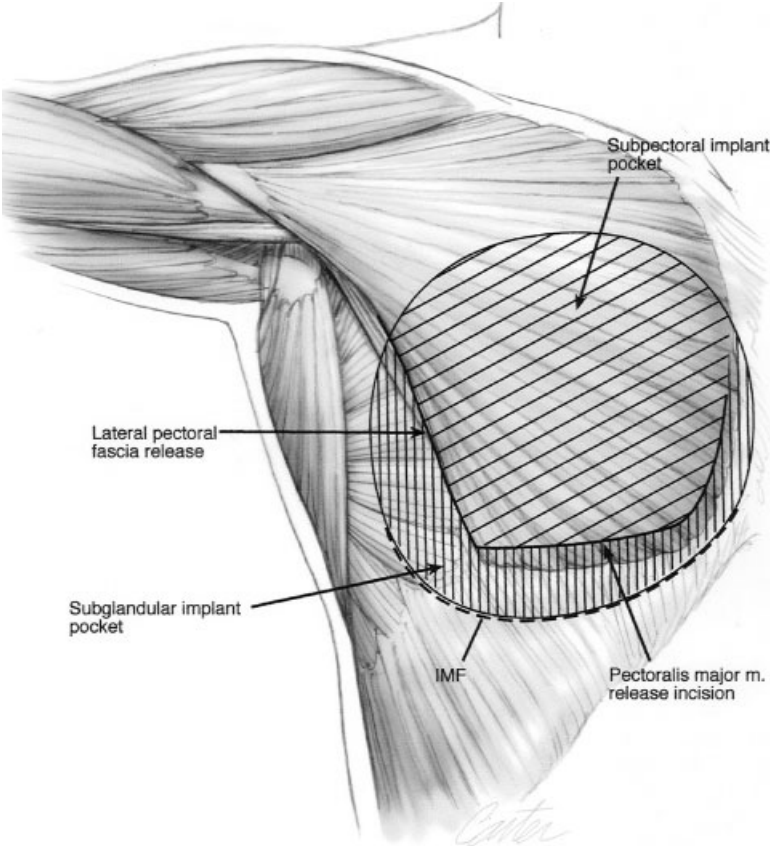
For the subglandular implant, a pocket is precisely dissected under direct visualization with lighted retractor and electrocautery. A pocket is created between the pectoralis muscle fascia and the gland, limiting the lateral extension over the serratus and inferior dissection to the inframammary fold. Medial dissection is to match the desired medial breast border, and the superior dissection should be high enough to allow sufficient re-draping of the glandular tissue without encouraging excessive migration of the implant (Fig. 6).

For a partial subpectoral implant or "dual-plane" implant, the procedure begins with an inferior subglandular dissection, which is kept limited to a small crescentic area between the inframammary fold and the nipple across the inferolateral region of the breast. The pectoralis muscle is then grasped with an Allis clamp, and the electrocautery is used to lift the pectoralis muscle along its inferior border. A urethral dilator may be used to quickly develop the upper half to two-thirds of the subpectoral pocket and serratus anterior (Fig. 7), staying on top of the pectoralis minor muscles. A minimal amount of blunt dissection is particularly helpful laterally to avoid errant dissection into the pectoralis minor or serratus anterior. The subpectoral pocket superiorly and the small subglandular pocket inferiorly must be made confluent by finishing the blunt dissection laterally and careful limited sharp release medially off the very lowest sternal origin of the pectoralis major (Fig. 8). This medial muscle release should be kept minimal and nearly always stay inferior to the nipple to avoid the risk of creating symmastia. After the implant has been inserted and its accurate position confirmed, the breast parenchyma is closed with resorbable sutures to cover the implant. The initial periareolar skin incision is then tacked with one or two sutures or staples and the patient is positioned upright. The nipple position and degree of ptosis is critically reassessed. If the additional volume of the implant proves inadequate to correct the skin laxity or degree of ptosis, simultaneous periareolar mastopexy may now be performed. The anticipated mastopexy can be tailor-tacked with sutures or staples to conform the position of the nipple.

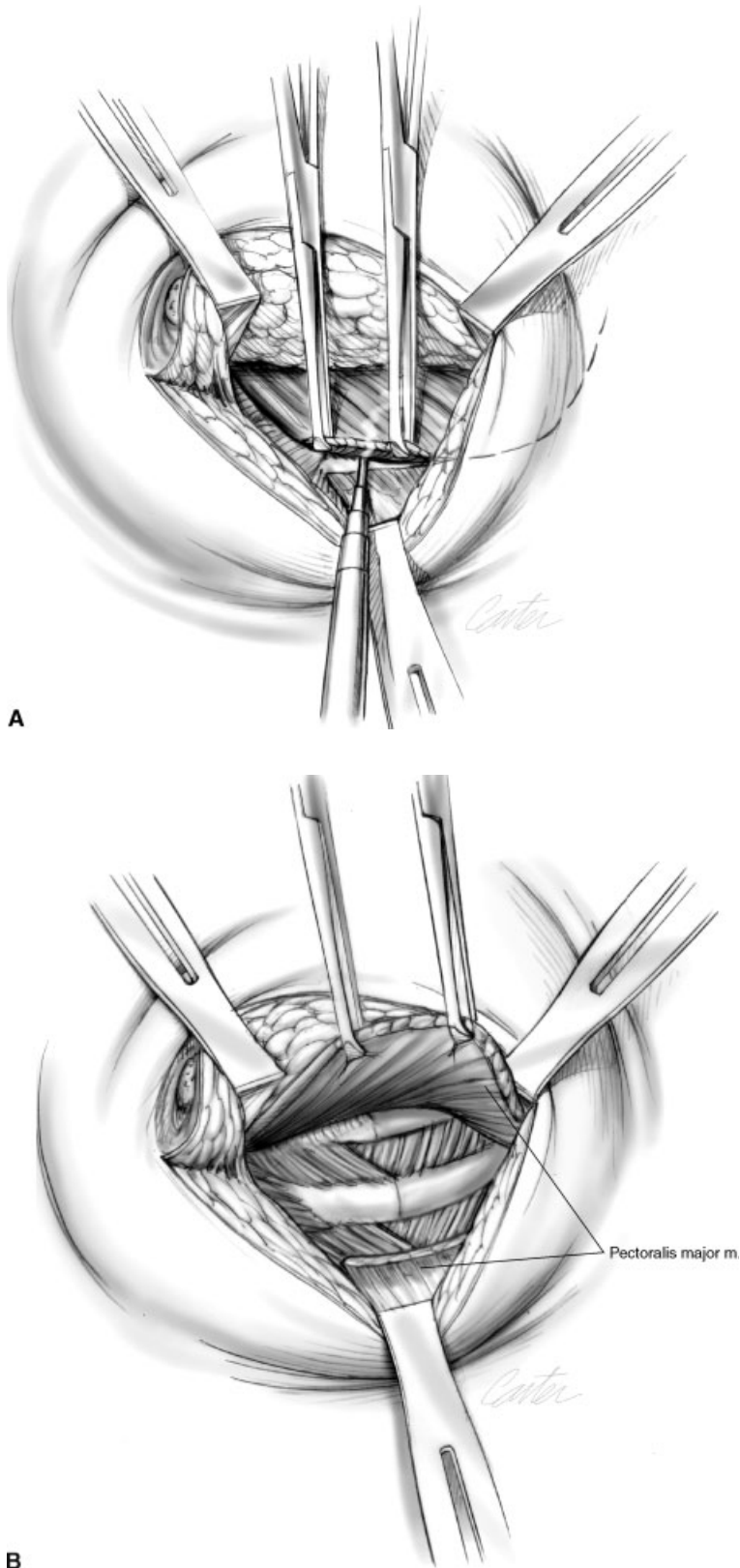
For periareolar mastopexy, the areola should have been marked previously with a reduced size between 38 and 50 mm. The marking is now confirmed and the appropriate areolar and periareolar skin to be excised is de-epithelialized. The dermis is incised between the remaining areola and breast skin. They are not left in continuity but preserved for secure closure later. The incision of the associated dermis decreases associated pincushioning. The authors prefer incising the dermis 4 to 5 mm more proximal to the nipple than the outer edge of the mastopexy circle. This leaves a narrow cuff or "fringe" of dermis in which to place the eventually "blocking" or circlage purse-string suture. The skin of the breast is the undermining in a very superficial plane,



**Figure 5** Oblique dissection through the breast parenchyma to the lateral pectoral border. An adequate inferior flap thickness is essential to cover the implant.



**Figure 6** The subglandular implant pocket is outlined.



A

B

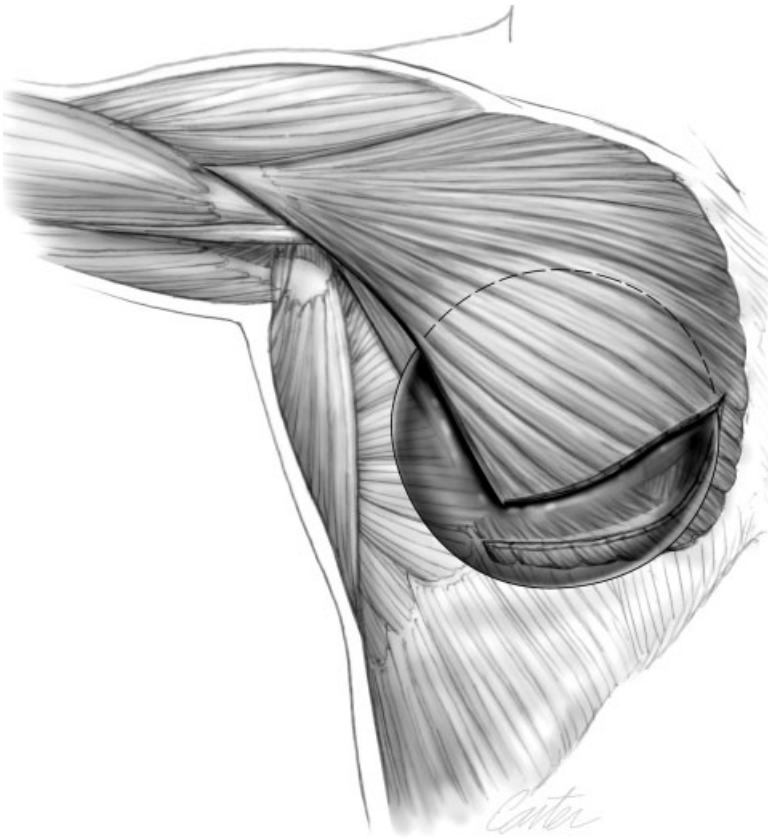
**Figure 7** The subpectoral dissection commences at the lateral pectoral border and extends from 7 to 4 o'clock.

circumferentially outward for at least 1 cm to allow tissue redraping (Fig. 9).

A purse-string suture is then placed. In the authors' experience, the suture of choice has been 3.0

Mersiline or Goretex. Regardless of the suture, a straight needle serves best to allow the suture to carefully follow the dermal fringe of the cut breast skin. This minimizes the periareolar scalloping often observed

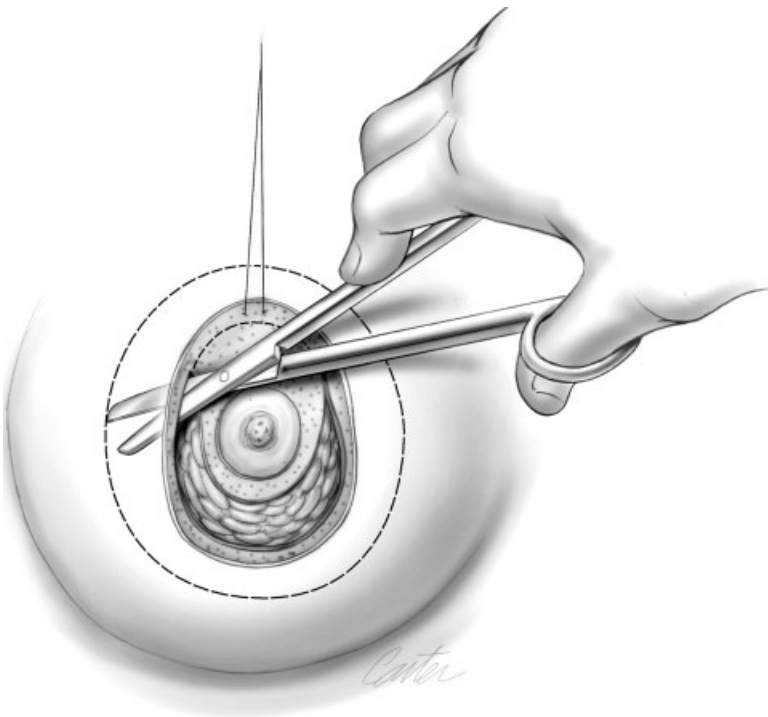




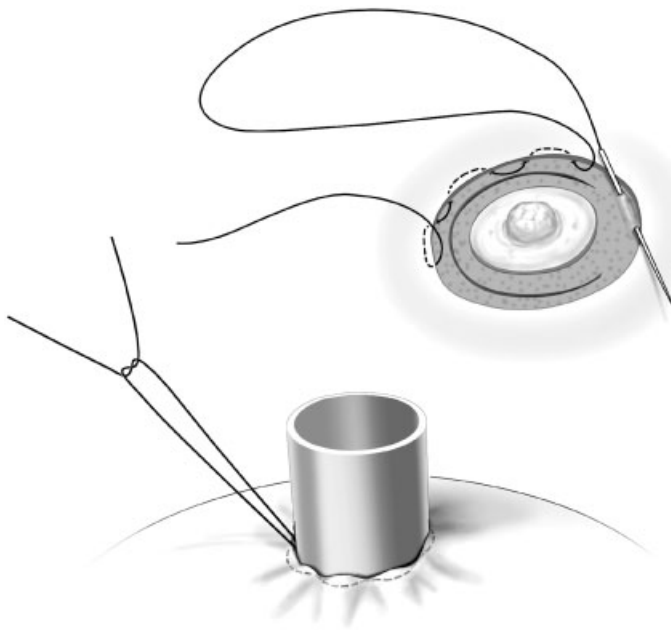
**Figure 8** Partial subpectoral and subglandular position of the implant.

when a half-curved needle is used. A 38-mm cookie cutter is used as a guide to the shape and size of the areola as the suture is tied (Fig. 10). Final closure is achieved with an interrupted and running intradermal

PDS, Monocryl (Ethicon, Sommerville, NJ), or cuticular running nylon suture. These last sutures are placed at the cut skin and areola edges, thus burying the purse-string suture behind the thick areola skin.



**Figure 9** The periareolar skin is de-epithelialized and the breast skin is undermined for redraping.



**Figure 10** The periareolar mastopexy is closed with a purse-string closure using Goretex or Mersiline on a straight needle. The suture is cinched down around a cookie cutter. Use of the straight needle allows the suture to stay along the cut dermal edge, minimizing the scalloping of the breast skin edge.

## POSTOPERATIVE CARE

Postoperative care starts immediately with appropriate dressing. The periareolar incisions are covered with an adherent semipermeable synthetic dressing such as Tegaderm (3M, St. Paul, MN) or Opsite (Smith & Nephew, London, UK) with a hole cut out for the nipple.

As in any breast procedure, the patient should be monitored carefully, particularly within the first few days to watch for signs of ischemia, infection, or bleeding. Depending on the circumstances, appropriate intervention may be necessary.

## CASE STUDIES

### Case Study 1

Patient with breast involution after breastfeeding. The right nipple is just below grade 1 and the left between 1 and 2 cm below the inframammary fold. Initial augmentation alone with 240-mL saline implant was inadequate and a periareolar mastopexy was needed to reduce the skin envelope. Results shown at 9 months (Fig. 11).

### Case Study 2

Patient with the nipple near the fold and 1 to 2 cm of glandular ptosis. Bilateral subpectoral augmentation with 200-mL silicone gel round implants and a circum-areolar mastopexy. Results shown at 1 year (Fig. 12).

### Case Study 3

Patient with 1 cm of nipple ptosis and 3 cm of breast ptosis. Bilateral subpectoral augmentation with round

saline implant with periareolar mastopexy. Results shown at 1 year (Fig. 13).

### Case Study 4

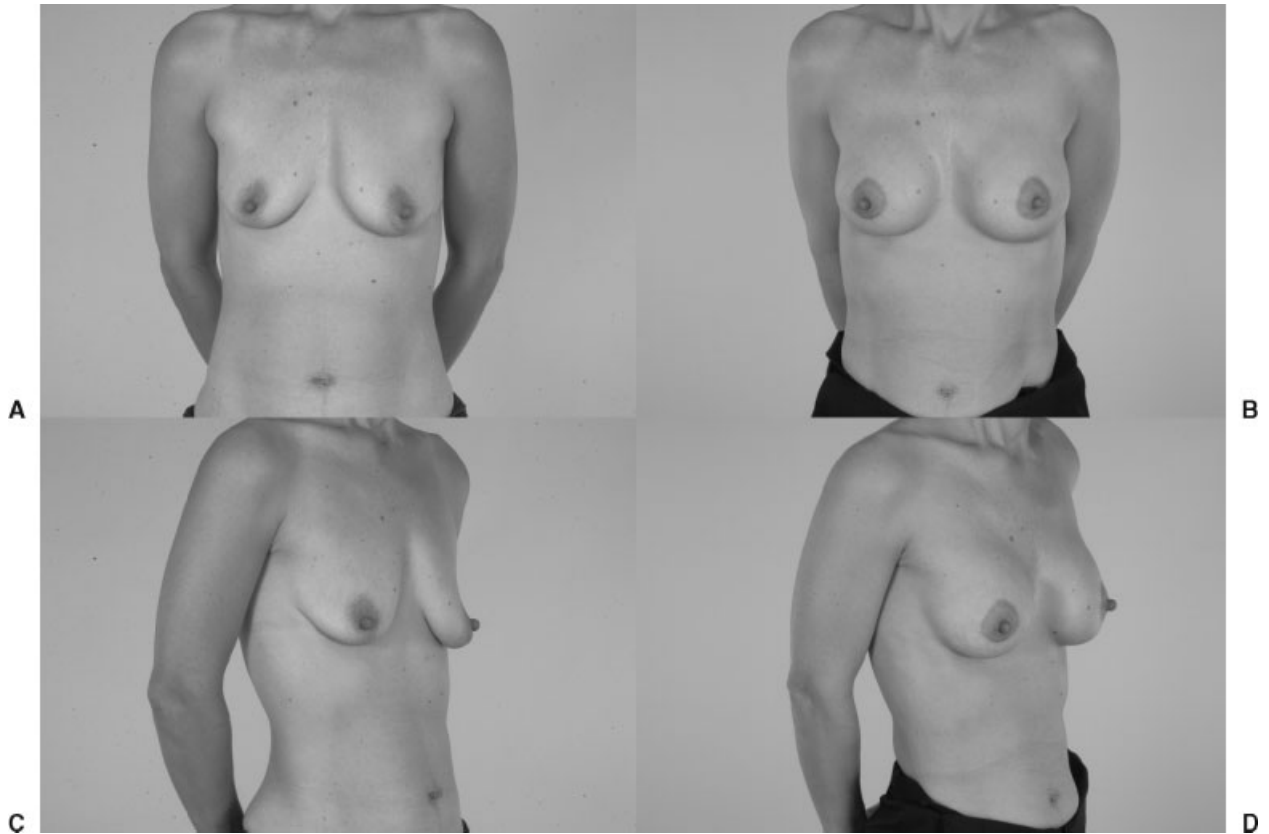
Patient with 2 cm of nipple ptosis and 3 to 4 cm of breast ptosis. Augmentation with periareolar mastopexy and round subpectoral silicone implant. Results shown at 1 year (Fig. 14).

## CONCLUSIONS

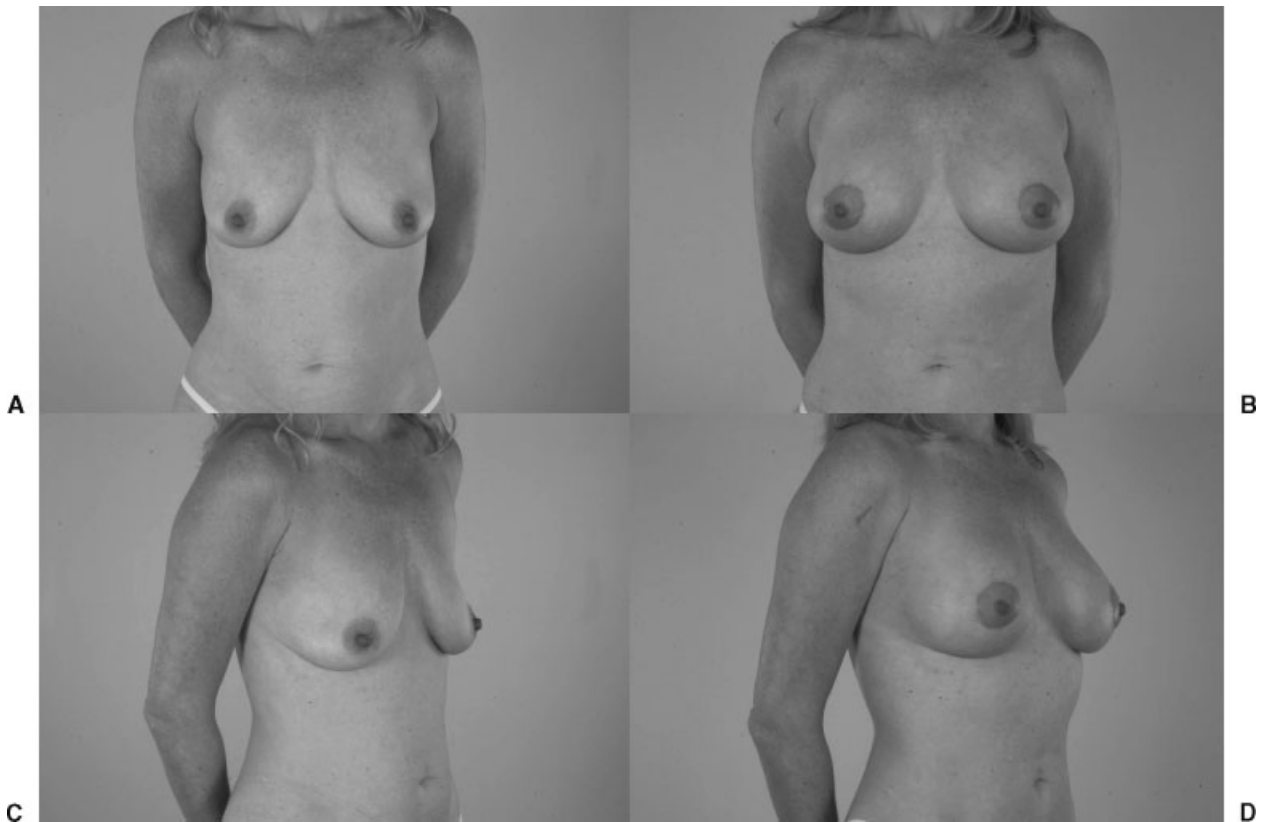
Augmentation with periareolar mastopexy can be an excellent tool in the appropriate situation to correct problematic ptosis for the patient who is seeking augmentation but who would otherwise achieve an unattractive result.

The periareolar mastopexy addresses the lax skin envelope, pseudoglandular ptosis, or first-degree or mild second-degree breast ptosis. The mastopexy repositions the nipple, while the implant restores the volume. Keeping the incision periareolar eliminates the vertical component and may help hide the scar. The purse-string permanent suture is key to preventing the areolar enlargement and scar spread often seen with other methods. A disadvantage of this technique is that the potential of the mastopexy is limited. If used injudiciously, flattening of the breast, areolar distortion, and poor scars may result.

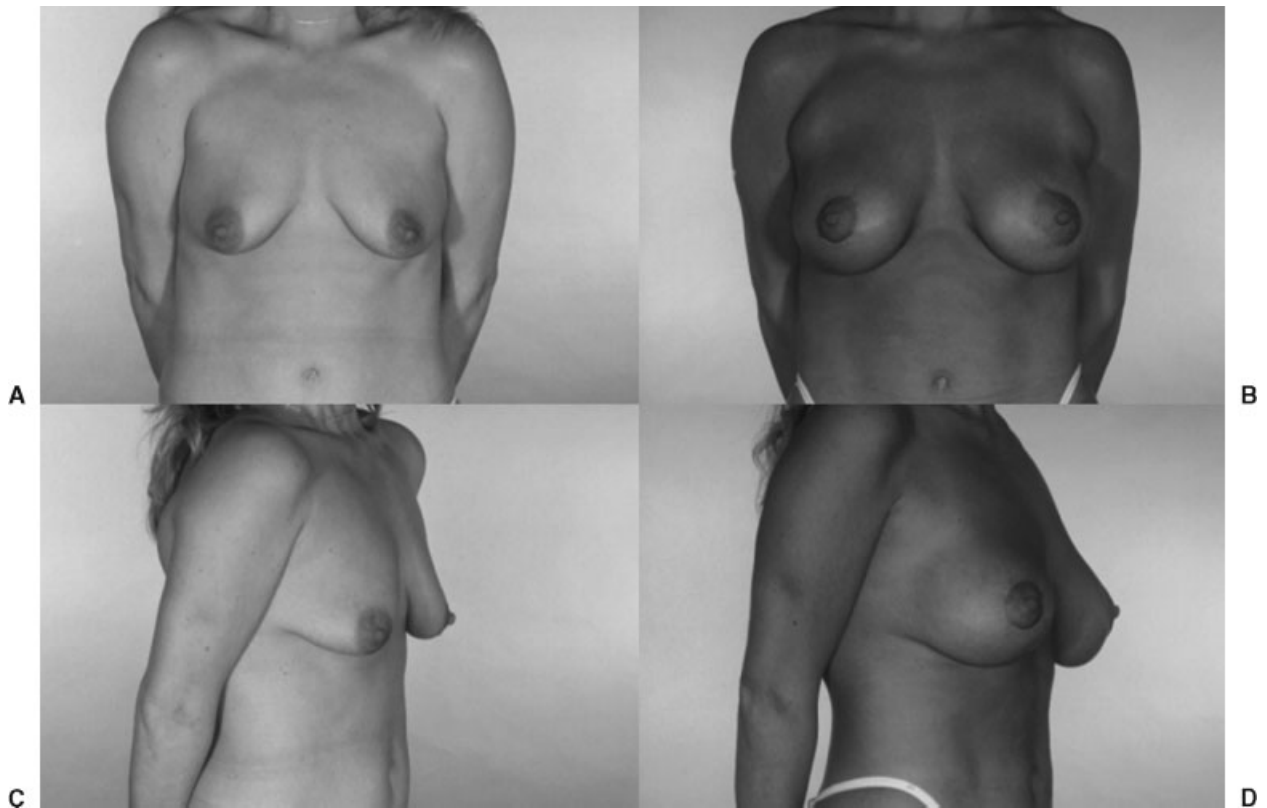
As the goals of mastopexy and augmentation are opposing, the risks involved in reducing the soft tissue envelope while simultaneously filling the volume are increased. The blood supply to the breast after subglandular augmentation is significantly and permanently



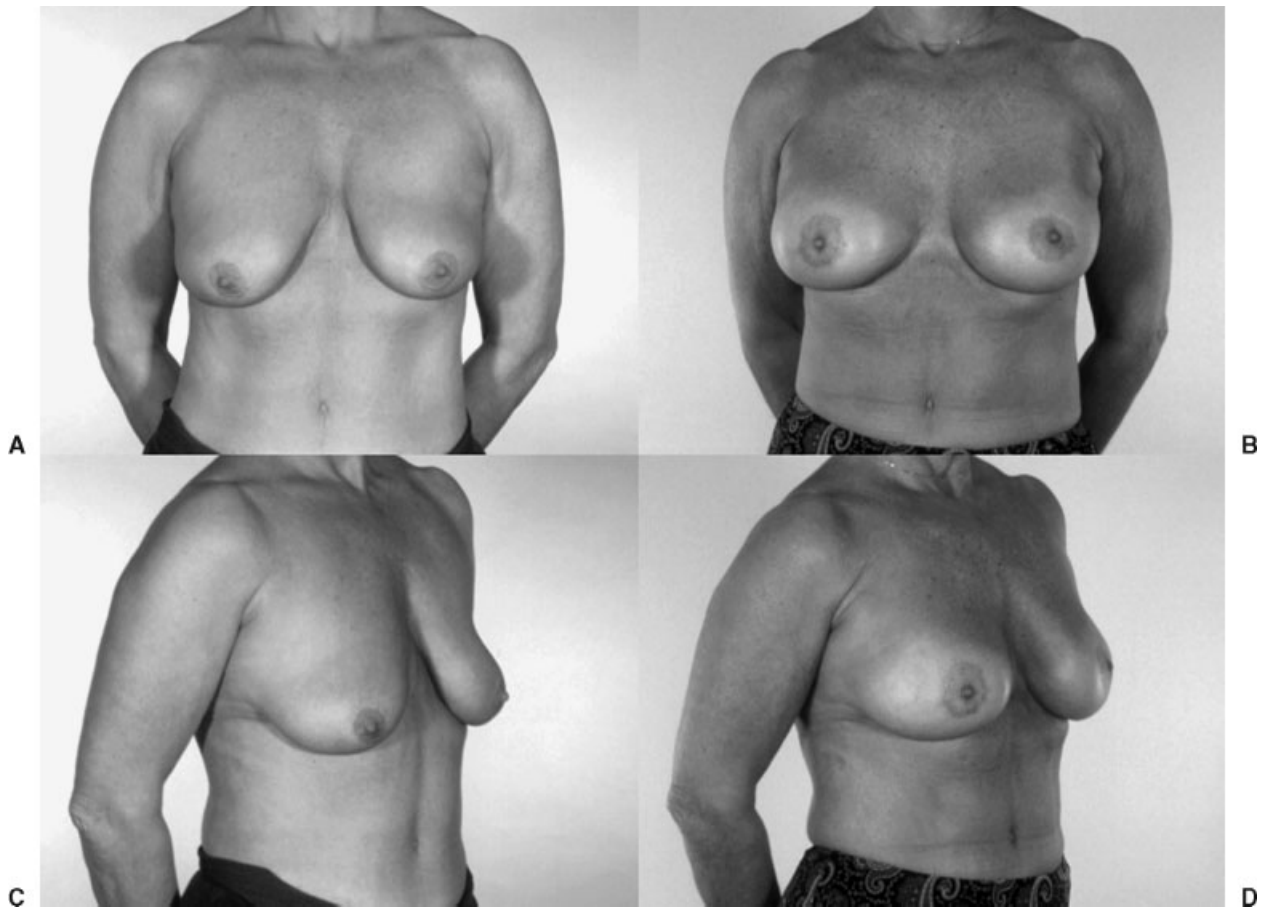
**Figure 11** Patient with breast involution after breastfeeding. (A, C) Nipple is just below grade 1. (B, D) Nipple is 1.5 cm below the inframammary fold. Initial augmentation alone with 240-mL saline implant was inadequate and a periareolar mastopexy was needed to reduce the skin envelope. Results shown at 9 months (case study 1).



**Figure 12** (A–D) Patient with the nipple near the fold and 1 to 2 cm of glandular ptosis. Bilateral subpectoral augmentation with round 200-mL gel round implants and a circumareolar mastopexy. Results shown at 1 year (case study 2).



**Figure 13** (A–D) Patient with 1 cm of nipple ptosis and 3 cm of breast ptosis. Bilateral subpectoral augmentation with round saline implant with periareolar mastopexy. Results shown at 1 year (case study 3).



**Figure 14** (A–D) Patient with 2 cm of nipple ptosis and 3 to 4 cm of breast ptosis. Augmentation with periareolar mastopexy and round subpectoral silicone implant. Results shown at 1 year (case study 4).

compromised, making simultaneous or even subsequent mastopexy or reduction riskier.

## REFERENCES

1. Gonzales-Ulloa M. Correction on hypertrophy of the breast by means of exogenous material. *Plast Reconstr Surg* 1960;25:15–26
2. Persoff MM. Mastopexy with expansion augmentation. *Aesthetic Plast Surg* 2003;27(1):13–19
3. Benelli L. A new periareolar mammoplasty: the “round block” technique. *Aesthetic Plast Surg* 1990;14(2):93–100
4. Regnault P. The hypoplastic and ptotic breast: a combined operation with prosthetic augmentation. *Plast Reconstr Surg* 1966;37:31–37
5. Owsley JK Jr. Simultaneous mastopexy and augmentation for correction of the small, ptotic breast. *Ann Plast Surg* 1979; 2(3):195–200
6. Gruber RP, Jones HW Jr. The “donut” mastopexy: indications and complications. *Plast Reconstr Surg* 1980;65(1):34–38
7. Puckett CL, Meyer VH, Reinisch JF. Crescentic mastopexy and augmentation. *Plast Reconstr Surg* 1985;75(4):533–539
8. Spear SL, Kassan M, Little JW. Guidelines in concentric mastopexy. *Plast Reconstr Surg* 1990;85(6):961–966
9. Baran CN, Peker F, Ortak T, Sensoz O, Baran NK. Unsatisfactory results of periareolar mastopexy with or without augmentation and reduction mammoplasty: enlarged areola flattened nipple. *Aesthetic Plast Surg* 2001;25(4):286–289
10. Spear SL. Augmentation/mastopexy: “surgeon, beware.” *Plast Reconstr Surg* 2003;112(3):905–906
11. Spear SL, Low M, Ducic I. Revision augmentation mastopexy: indications, operations, and outcomes. *Ann Plast Surg* 2003;51(6):1–7
12. Maxwell GP. Breast asymmetry. *Aesthetic Surgery Journal* 2001;121(6):473–588
13. Karnes J, Morrison W, Salisbury M, Schaeferle M, Beckman P, Ersek RA. Simultaneous breast augmentation and lift. *Aesthetic Plast Surg* 2000;24(2):148–154