

Modified Circumferential Torsoplasty for the Massive-Weight-Loss Patient

Steven P. Davison, MD, DDS,* Mark W. Clemens, MD,* and Suzie Chang, MD†

Background: Obesity is an increasing national public health issue that has reached epidemic proportions over the past several decades. With new surgical advances in bariatric surgery, the massive-weight-loss patient population is on the rise. The generalized redundancy of skin following massive weight-loss, including lateral flank rolls, abdominal excesses, and buttock ptosis, is a problem amenable only by surgical excision. The circumferential torsoplasty has enabled the plastic surgeon to dramatically help this patient population. However, a problem exists in a size mismatch of the abdomen between the upper and lower circumferential flaps, leading to contour deformities.

Methods: This study reports on 3 cases of circumferential torsoplasty, with modified lateral skin wedge resection treated by a single surgeon. The preoperative markings, technical aspects of the surgery, postoperative care, and outcomes are reviewed.

Results: Patients in all 3 cases achieved improved body contour. To date, there have been no postoperative complications of the study participants.

Conclusion: We propose a new modification to the circumferential torsoplasty that simultaneously eliminates the lateral dog-ears and prevents recurrence of saddlebag deformities commonly encountered in the traditional circumferential torsoplasty. A wedge excision of lateral thigh skin to deep investing fascia is primarily closed and simultaneously equalizes flap length and tightens the thigh area. The scars are well accepted by patients.

Key Words: circumferential torsoplasty, massive weight loss

(*Ann Plast Surg* 2007;59: 453–458)

In the past decade, the prevalence of obesity has been an increasing national public health concern in the United States and across the world.^{1,2} The rise in obesity has led to a concomitant increase in the number of gastric bypass procedures. The American Society of Bariatric Surgery reports an increase in bariatric surgeries of 450% between

1998 and 2002, with approximately 140,000 in 2004 and 170,000 in 2005.³ With the success of bariatric surgery in maintaining long-term weight-loss, surgical therapy remains the best long-term option for many morbidly obese patients.⁴ This trend in bariatric surgery is of particular interest to plastic surgeons that perform post-gastric bypass body-contouring procedures.⁵ These procedures have increased 77% between 2000 and 2004, the most recent year statistics are available.⁶ The American Society of Plastic Surgeons reported approximately 106,000 body-contouring procedures were performed in 2004, with 56,000 occurring in bariatric surgery patients. From 2003 to 2004, upper arm lifts and thigh lifts increased 57% and 61%, respectively.

With the growing number of bariatric surgery patients, the massive-weight-loss patient population is on the rise. The generalized redundancy of skin following massive weight loss is an esthetic and, often, a functional problem that remains amenable only by surgical excision.⁷ This study focuses on those patients who present with severe contour deformities, or Pittsburgh class III deformities of the buttocks, thighs, and abdomen, requiring combinations of excision and lifting, involving large areas of undermining.⁸ These patients display significant epigastric dimensions, with major ptosis of adipose-filled rolls, complicated by a double pannus with obvious skin folds. The surgical challenge inherent to this population emphasizes the need for a refined contouring procedure.

In the armamentarium of surgical procedures available to the plastic surgeon, the circumferential torsoplasty has dramatically advanced the degree of change brought upon by any single surgical procedure to the massive-weight-loss patient. During the conventional circumferential torsoplasty, the lampshade technique is used by pulling the upper abdominal circumferential flap directly down to approximate with the lower abdominal circumferential flap.⁹ This technique has the inherent problem in its creation of a length mismatch between the upper and lower circumferential flap. Normally, this length discrepancy is addressed by differential suturing to distribute excess skin and minimize lateral dog-ears. However, this strategy is usually inadequate in addressing loose, ptotic skin envelopes and can lead to contour irregularities, skin pleating, and palpable wrinkling of the skin, especially in severe Pittsburgh stage III patients.

We propose a modified approach to the traditional circumferential torsoplasty for a further improvement in body contour in the massive-weight-loss patient following

Received November 5, 2006, and accepted for publication December 4, 2006.

From the *Georgetown University Medical Center, Washington, DC; and the †University of Texas Southwestern Medical Center, Dallas, TX.

Reprints: Steven P. Davison, MD, DDS, Department of Plastic Surgery, Georgetown University Medical Center, 3800 Reservoir Road NW, NW, 1-PHC, Washington, DC 20007. E-mail: Spd2@georgetown.edu.

Copyright © 2007 by Lippincott Williams & Wilkins

ISSN: 0148-7043/07/5904-0453

DOI: 10.1097/01.sap.0000258496.77525.69

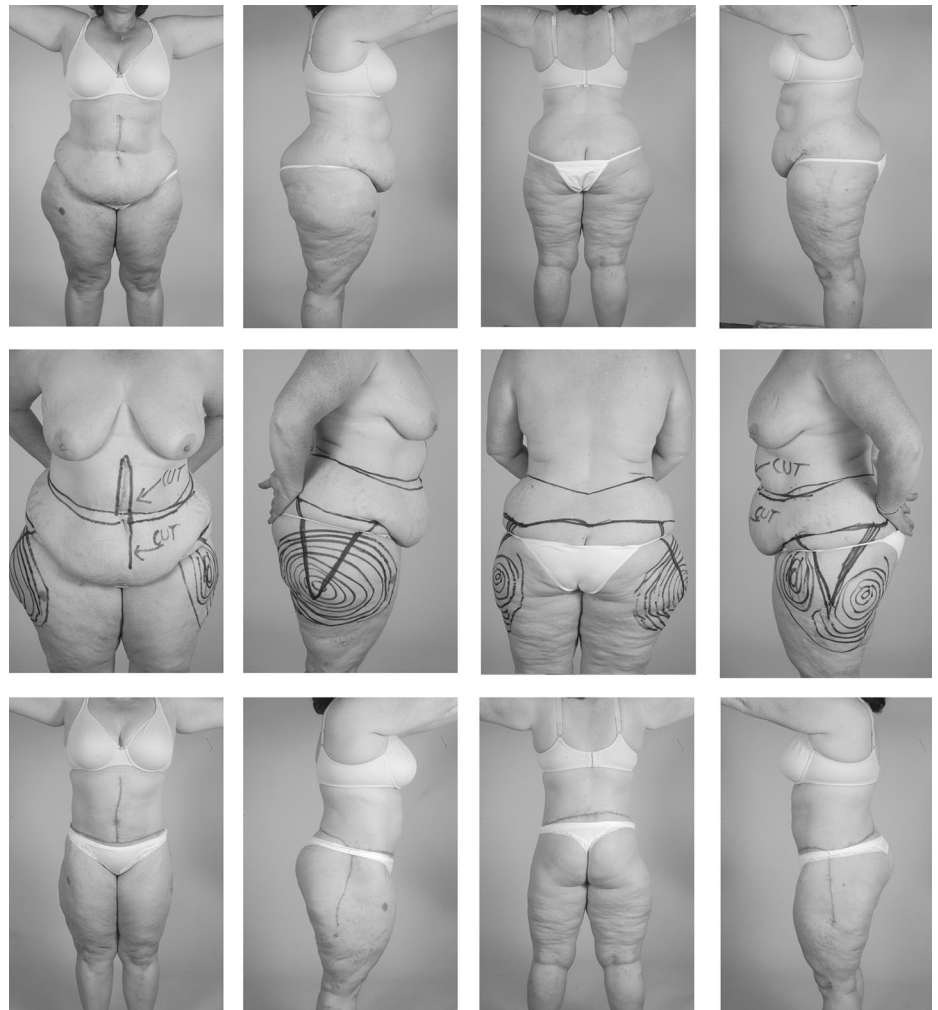


FIGURE 1. Improved skin redundancy in the thighs after belt lipectomy of patient 1, a 45-year-old female. Body mass index highest, 41, low, 29. Top, preoperative views. Middle, marking of the patient for lower body lift. Bottom, 5 months postoperatively.

bariatric surgery, as illustrated in the following 3 case reports.

METHODS

This technique is to wedge excise a portion of the saddlebag thigh down to investing fascia and excise it in the vertical plane, placing the incision approximately where the seam is in a pair of pants. This excision is placed slightly posterior to the median of the thigh and dropped vertically from the posterior iliac crest. The patient is marked preoperatively in the standing position. The circumferential skin excision is estimated in standard fashion by using the pinch test. Then, a lateral wedge at the side of the thigh is marked. This planned wedge is extended inferiorly to pull as much of the lateral thigh as needed while simultaneously limiting the length of the scar. Deep liposuction is used to undermine the upper lateral thigh, and the wedge is excised. The thigh is closed prior to the lateral closure of Scarpa fascia between the upper and lower circumferential skin flaps. There is no undermining of the skin flaps, which might compromise the vascular supply at the t-junction.

RESULTS

Case 1

The patient was a Pittsburgh class III 45-year-old female status post-gastric bypass, with a subsequent decrease in BMI from 41 to 29 kg/m² (Fig. 1). The patient lost 80 pounds, is currently 211 pounds, and has a stature of 5 feet 11 inches. The patient came in for a circumferential body lift. However, on evaluation, she has a substantial amount of skin excess in the abdomen, lateral aspect of the flanks, and particularly the saddlebag area. The patient's past surgical history was significant for a hip replacement surgery for degenerative arthritis related to her obesity, which resulted in a vertical scar on the left lateral aspect of the hip. A 20-cm portion of skin was removed horizontally to reduce the discrepancy between the upper flap and the inferior flap. The previous hip approach scar was used, and a contralateral symmetrical scar was placed on the right hip. After 1 year of follow-up, the patient has done extremely well, with no postoperative complications. The contour of her abdomen, flank, and thigh is ideal.

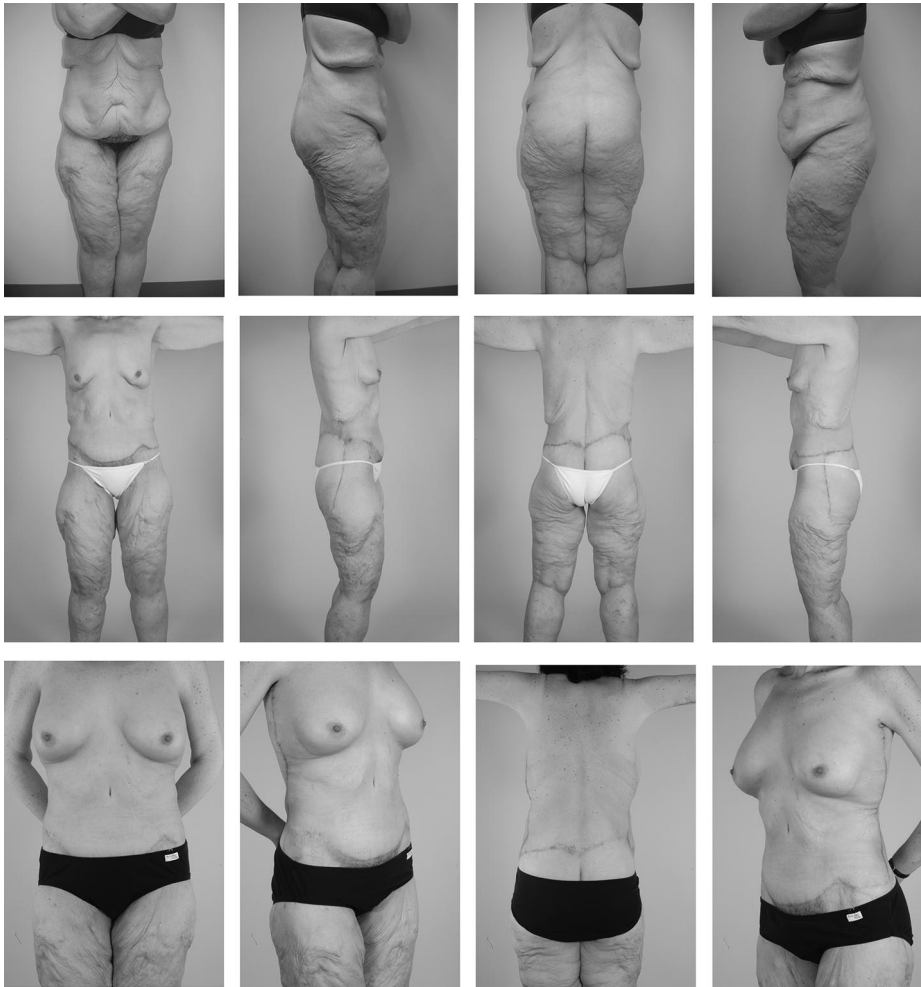

FIGURE 2. Enhanced contour in the thighs after belt lipectomy of patient 2, a 39-year-old female. Body mass index highest, 51, low, 32. Top, pre-operative views. Middle, 12 months postoperatively. Bottom, note 21 months postoperatively that posterior placement of scars is less visible from the front, which is more cosmetic in the view patients usually see.

Case 2

The patient is a 39-year-old female who lost 185 pounds after gastric banding and presented demonstrating Pittsburgh class III contour deformities of the abdomen, thighs, and buttock following a decrease in BMI from 51 to 32 kg/m² (Fig. 2). The patient has a substantial laxity of skin, with 40 cm of excess skin on the anterior aspect of the abdomen, 35 cm of skin on the lateral flanks, and 25 cm of skin on the posterior aspect of the back. In addition, the patient lost a substantial amount of weight and volume from the lateral aspect of the thighs, giving her considerable redundancy. The patient underwent a circumferential body lift with wedge excision of skin on the lateral aspect of the thigh. The patient had an uneventful postoperative recovery, with 21 months' follow-up. The patient is delighted with the postoperative contour associated with the circumferential body lift.

Case 3

The patient is Pittsburgh class III 51-year-old female who had lost 185 pounds, is currently 197 pounds, and has a stature of 5 feet 8 inches (Fig. 3). Her calculated BMI has gone from 58 to 30 kg/m². The patient presented with a

substantial amount of excessive skin on the lateral aspect of the thighs, with a discrepancy between the upper skin flap and the lower skin flap. Therefore, the patient underwent a mastopexy and simultaneous circumferential torsoplasty, with a wedge excision of skin on the lateral aspect of the thighs measuring 15 cm across, which reapproximated the superior and inferior flap discrepancies, reduced the dog-ear, and gave an ideal contour to the circumferential body lift. The patient is 18 months after surgery and has done extremely well, with no complications.

DISCUSSION

The circumferential torsoplasty is a circular excision of excess skin and adipose tissue found in the abdominal, lower flank, and lower back areas of the bikini-line region. This procedure has been described in various terms' including belt lipectomy, body lift, central body lift, lower body lift, circumferential panniculectomy, and circumferential lipectomy.¹⁰⁻¹²

The circumferential torsoplasty was first described in 1960 as the "belt lipectomy" by Gonzalez-Ulloa.¹³ His technique involved anterior and posterior midline vertical wedge

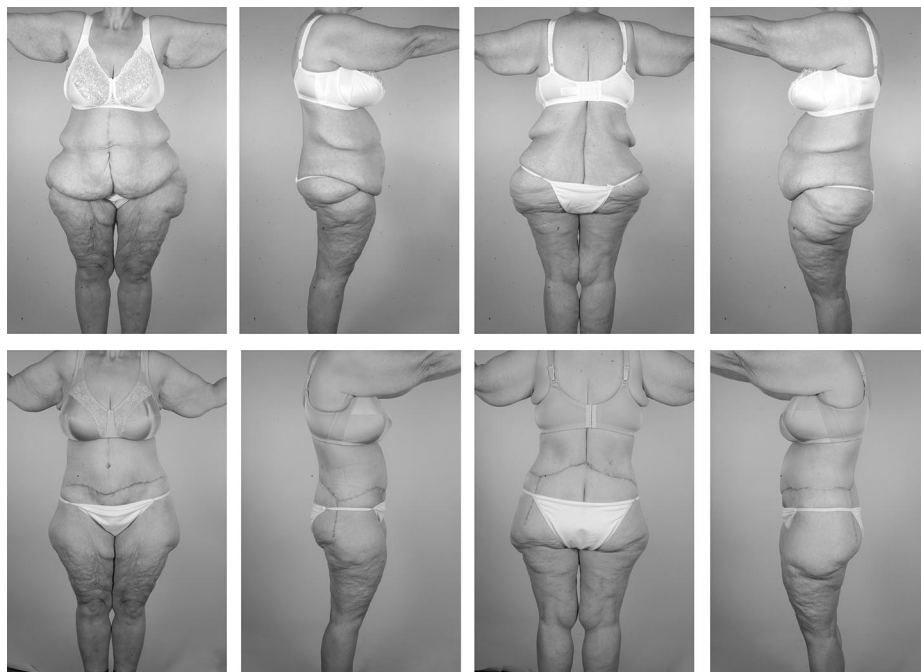


FIGURE 3. Improved match between upper and lower circumferential flaps in a 51-year-old female after body mass index reduction from 58 to 30. Top, preoperative views. Bottom, 18 months postoperatively.

resections to achieve circumferential excision of skin redundancies. Little has been published regarding these procedures, with most papers describing indications, patient satisfaction, and commonly encountered complications found in a few small studies (Table 1: published studies).

The traditional circumferential torsioplasty involves many steps, including meticulous preoperative markings, multiple intraoperative positional changes of the patient, and careful postoperative care requiring the patient to remain in positions of least possible tension in closure

TABLE 1. Published Studies

Authors	Publication Date	Study Findings
Gonzalez-Ulloa M ¹³	1960	First published account describing the circumferential torsioplasty
Dardour JC and Vilain R ¹⁴	1986	300-Patient series describing various abdominoplasty techniques; not devoted exclusively to circumferential torsioplasty
Lockwood TE ¹⁵	1991	Description of the superficial fascial system (SFS) of the torso and extremities
Lockwood TE ¹⁶	1991	10-Patient series reporting indications and utilization of the SFS in high-tension-lateral closure in the transverse flank-thigh-buttock lift
Lockwood TE ¹⁷	1993	Description of his “lower body lift #1” (lower flank/thigh/buttock lift combined with upper medial thighplasty)
Hunstad JP ¹⁸	1996	Description of combined technique of circumferential torsioplasty and liposuction for improved body contouring in obese patients. Reported high rate of seroma formation
Carwell GR and Horton CE ¹⁹	1997	7-Patient series on circumferential torsioplasty utilizing 4-blade propeller pattern for rectus plication
Van Geertruyden JP et al ²⁰	1999	30-Patient series on circumferential torsioplasty noting minor complication rates and 1 major complication with increased patient/surgeon satisfaction
Hamra ST ²¹	1999	40-Patient series on circumferential torsioplasty utilizing multiple positional changes (both lateral and decubitus positions). Reported small complication rates for seroma formation and increased patient/surgeon satisfaction.
Lockwood TE ²²	2001	Description of his “lower body lift #2” technique: staging the transverse medial thighplasty after the lower flank/thigh/buttock lift
Aly AS et al ⁹	2003	32-Patient series and literature review of the circumferential torsioplasty. Reported high seroma complication rate, low pulmonary embolus rate, and 1 dehiscence
Hurwitz DJ ²³	2004	9-Patient series utilizing combined circumferential torsioplasty with medial thighplasty, modified with positioning of thigh in full abduction before closure in the prone position. Reported correction of saddlebag deformity with new grading system
Van Huizum MA ²⁴	2005	21-Patient series of circumferential torsioplasty designed to evaluate perioperative complications. Reported minor complications and good patient satisfaction

incisions. With Lockwood's²⁵ significant contribution of utilization of the superficial fascial system (SFS), most published accounts employ the high-tension lateral closure in the abdominal portion of the circumferential torsoplasty.²⁶

The traditional circumferential torsoplasty involves the challenge of proper elimination of lateral dog ears formed by the discrepancy in lengths of the superior versus inferior circumferential flaps created after excision of the circumferential panel. Strategies used to eliminate the lateral dog-ears include lower placement of the inferior incision in the mons pubis region,²⁴ vertical or transverse medial thighplasty,^{22,23,27} and concomitant liposuction of the lateral thigh region.^{18,28}

Despite preservation and tight approximation of the SFS, the traditional circumferential torsoplasty procedure cannot correct severe saddlebag deformities. It has been noted that the preoperative skin excesses found in the upper lateral thigh are usually improved at the time of suture removal but partially reappear within 1 year postoperatively. This saddlebag deformity is thought to be due to the abnormal increase in tissue elasticity present in the skin of massive-weight-loss patients.²³

One study addresses the problem of persistent saddlebag deformity in the circumferential torsoplasty massive-weight-loss patient. This retrospective review of 9 patients examined a modified technique to the traditional circumferential torsoplasty, with the addition of the medial thighplasty utilizing full abduction positioning of each operated thigh.²³ However, this removal of medial skin is distant from the area of skin excess. Therefore, the resultant vector force of the excision is lost. In this patient population, scar length and scar issues are not the predominant issue. Therefore, we propose directly excising the offending skin. Prevention of the recurring saddlebag deformity was an aim of this paper's technique and was successful at over a year's follow-up.

We propose a modification in technique to the traditional circumferential torsoplasty procedure. This includes placement of a scar slightly posterior, which is less obvious when a patient is looked at from an anterior view. This new technique was used in the presented 3 case reports. By incorporating a wedge excision at the lateral thigh region inferior to the circumferential flap incision line, we eliminate both the lateral dog-ears and future possibility of recurrent saddlebag deformities. This is done by reducing gravitational load in the lateral thigh region by the wedge excision of tissue normally left intact, thus leaving less tissue to undergo further ptosis.

As reported, direct excisions are advocated as extensions of the brachioplasty to address excess skin in body contouring surgery of the upper body. It makes sense to address issues of skin excess of the lower body in a similar manner. Although the placement of this scar goes against plastic surgery dogma, it is where tailors have placed pant leg seams for generations. We are in fact making the patient a new bespoke suit of skin.

By incorporating this lateral wedge excision into the circumferential torsoplasty procedure, we eliminate the

need for later revisions that may be technically demanding and not always successful in the setting of a now-dissatisfied patient. Most patients are more concerned with their appearance in clothes and more accommodating of scars than other surgery patients.

CONCLUSION

The generalized redundancy of skin following massive weight loss, including lateral flank rolls, abdominal excesses, and buttock ptosis, is a problem amenable only by surgical excision. The circumferential torsoplasty has enabled the plastic surgeon to dramatically help this patient population. We propose a new wedge modification that simultaneously eliminates the lateral dog-ears and prevents recurrence of saddlebag deformities commonly encountered in the traditional circumferential torsoplasty.

REFERENCES

1. Mokdad AH, Serdula MK, Dietz WH, et al. The spread of the obesity epidemic in the United States, 1991–1998. *JAMA*. 1999;282:1519.
2. Hedley AA, Ogden CL, Johnson CL, et al. Prevalence of overweight and obesity among US children, adolescents, and adults, 1999–2002. *JAMA*. 2004;291:2847.
3. Hellmich N. Gastric bypass surgery seeing big increase. *USA Today*. December 19, 2005.
4. National Institutes of Health Consensus Development Panel. Gastrointestinal surgery for severe obesity. *Ann Intern Med*. 1991;115:956.
5. O'Connell JB. Bariplastic surgery. *Plast Reconstr Surg*. 2004;113:1530.
6. Adler E. After gastric bypass, can body contouring surgery be far behind? *Morning Call, KRT News Service*. March 21, 2006.
7. Schechner SA, Jacobs JS, O'Loughlin KC. Plastic and reconstructive body contouring in the post-vertical banded gastroplasty patient: a retrospective review. *Obes Surg*. 1991;1:413.
8. Song AY, Jean RD, Hurwitz DJ, et al. A classification of contour deformities after bariatric weight loss: the Pittsburgh Rating Scale. *Plast Reconstr Surg*. 2005;116:1535.
9. Aly AS, Cram AE, Chao M, et al. Belt lipectomy for circumferential truncal excess: the University of Iowa experience. *Plast Reconstr Surg*. 2003;111:398.
10. Dabb RW, Hall WW, Baroody M, et al. Circumferential suction lipectomy of the trunk with anterior rectus fascia plication through a periumbilical incision: an alternative to conventional abdominoplasty. *Plast Reconstr Surg*. 2004;113:727.
11. Gracia HJM. Circular lipectomy with lateral thigh-buttock lift. *Aesthetic Plast Surg*. 2003;27:50.
12. Hurwitz DJ. Single-staged total body lift after massive weight loss. *Ann Plast Surg*. 2004;52:435.
13. Gonzalez-Ulloa M. Belt lipectomy. *Br J Plast Surg*. 1960;13:179.
14. Dardour JC, Vilain R. Alternatives to the classic abdominoplasty. *Ann Plast Surg*. 1986;17:247.
15. Lockwood TE. Superficial fascial system (SFS) of the trunk and extremities: a new concept. *Plast Reconstr Surg*. 1991;87:1009.
16. Lockwood TE. Transverse flank-thigh-buttock lift with superficial fascial suspension. *Plast Reconstr Surg*. 1991;87:1019.
17. Lockwood TE. Lower body lift with superficial fascial system suspension. *Plast Reconstr Surg*. 1993;92:1112.
18. Hunstad JP. Body contouring in the obese patient. *Clin Plast Surg*. 1996;23:647.
19. Carwell GR, Horton CE. Circumferential torsoplasty. *Ann Plast Surg*. 1997;38:213–216.
20. Van Geertruyden JP, Vandeweyer E, De Fontaine S, et al. Circumferential torsoplasty. *Br J Plast Surg*. 1999;52:623.
21. Hamra ST. Circumferential body lift. *Aesthetic Surg J*. 1999;19:244.
22. Lockwood TE. Lower-body lift. *Aesthetic Surg J*. 2001;21:355.
23. Hurwitz DJ, Rubin JP, Risin M, et al. Correcting the saddlebag defor-

- mity in the massive weight loss patient. *Plast Reconstr Surg.* 2004;114:1313.
24. Van Huizum MA, Roche NA, Hofer SOP. Circular belt lipectomy: a retrospective follow-up study on perioperative complications and cosmetic outcome. *Ann Plast Surg.* 2005;54:459.
 25. Lockwood TE. Lower body lift with superficial fascial system suspension. *Plast Reconstr Surg.* 1993;92:1112.
 26. Pascal JF, LeLosarn C. Remodeling body lift with high lateral tension. *Aesthetic Plast Surg.* 2002;26:223.
 27. Ellabban MG, Hart NB. Body contouring by combined abdominoplasty and medial vertical thigh reduction: experience of 14 cases. *Br Assoc Plast Surg.* 2004;57:222.
 28. Lockwood TE. Maximizing aesthetics in lateral-tension abdominoplasty and body lifts. *Clin Plast Surg.* 2004;31:523.