

The Zones of Adherence: Role in Minimizing and Preventing Contour Deformities in Liposuction

Rod J. Rohrich, M.D., Paul D. Smith, M.D., David R. Marcantonio, M.D., and Jeffrey M. Kenkel, M.D.

Dallas, Texas

True body sculpting demands a three-dimensional artistic understanding of the anatomic and surgical adipose layers of the central trunk when performing circumferential liposuction. This is essential in preventing complications from both ultrasound-assisted and suction-assisted lipoplasty. The authors describe five zones of adherence that should be avoided to prevent contour deformities in the central trunk area when performing circumferential liposuction. The anatomy of the subcutaneous tissue of these five anatomic zones is reviewed and correlated radiographically with magnetic resonance imaging studies. Aesthetic and technical considerations required to properly liposculpt the central trunk are demonstrated by case analysis of primary and secondary liposuction patients. These cases also delineate how to prevent and/or minimize deformities after liposuction. (*Plast. Reconstr. Surg.* 107: 1562, 2001.)

The subcutaneous adipose tissue of the body has recently received greater attention due to the increased popularity of suction-assisted body contouring. This increased popularity has paralleled the rise in the prevalence of increasing weight within the population. The largest increases in the use of liposuction occurred in the 18- to 29-year-old age group and in people with higher educations.¹ Modern liposuction mandates a circumferential approach to obtain an improved body silhouette, especially in the central trunk area.

During weight gain, the amount of fat in the subcutaneous tissues throughout the body increases proportionately. In other words, weight gain does not occur in selective areas.² However, the converse of this is not true. The obese patient, after reaching his or her ideal body weight, still maintains a disproportionate amount of subcutaneous fat in the waist and an

elevated waist-to-hip ratio when compared with control patients who were never obese.³ This is because weight loss occurs preferentially from the visceral fat stores as opposed to the subcutaneous stores. This is true regardless of whether the weight loss occurs with diet alone or with diet and exercise.⁴ The visceral adipose tissue represents 18 percent of total body fat. The largest amount of this visceral fat occurs at the level of the umbilicus, and the greatest amount of subcutaneous fat occurs in the region of the buttocks.⁵

The development of liposuction in the early 1980s allowed this unequal fat distribution in adipose tissues to be addressed surgically through minimal incisions.⁶ Liposuction requires a three-dimensional understanding of fat deposits, because optimal results are achieved currently using circumferential liposuction with combined suction-assisted and ultrasound-assisted techniques. Knowing which areas to avoid is basic to minimizing complications such as contour irregularities.

An understanding of the aesthetically pleasing human form is fundamental. The aesthetically pleasing female silhouette is recognized as a concavity below the rib cage that changes to a convexity over the hips and thighs. Both the anterior and posterior portion of the thighs should have a shallow convex arc. In addition, the female buttock crease should extend in a curvilinear fashion (rounded) to blend with the lateral thigh (Fig. 1). The female abdomen should be concave in the epigastrium, with a smooth transition to a convex lower abdomen.

In contrast, men have a more linear silhouette, with only relative concavities in the pelvic region and convexity in the buttocks area (square). The flanks should taper from the lower ribs to the iliac crest, and the buttock crease is more angular and square (Fig. 2).⁷ Furthermore, the anterior infraumbilical region should be flat rather than convex.

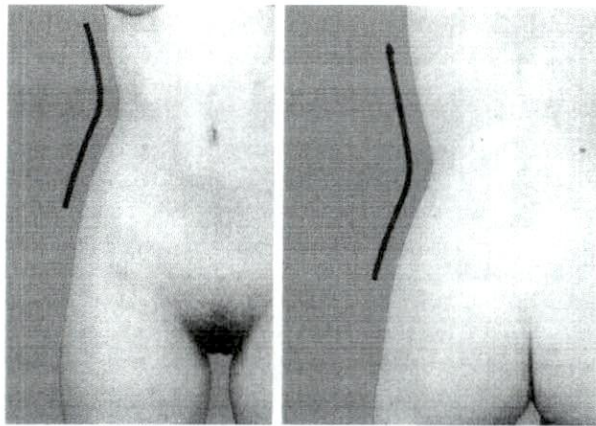


FIG. 1. (Left) The ideal female shape consists of a concavity below the rib cage that changes to a convexity over the hips and thighs. The medial and lateral thighs have mild convexities. (Right) The buttock crease is curvilinear as it blends laterally with the thigh in a rounded fashion.

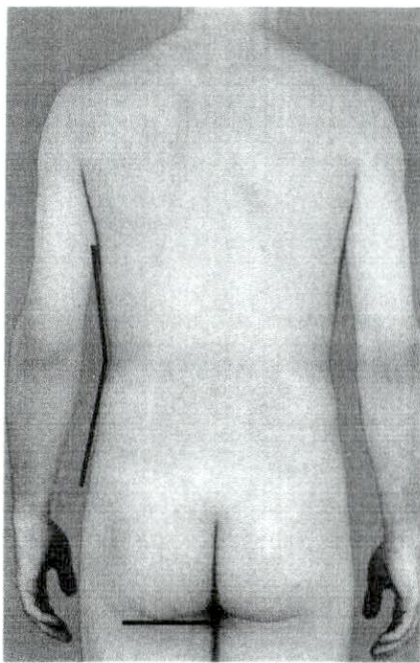


FIG. 2. The male figure has a more linear silhouette, with much less concavity and convexity below the rib cage and over the thighs. The buttock crease is squared and more linear in shape. The anterior infraumbilical region should be flat rather than convex.

ANATOMY

Gray's Anatomy describes the subcutaneous adipose tissue of the abdomen as being separated into two distinct fascial planes.⁸ Markman and Barton⁹ examined the ultrastructure of these layers and characterized them as a superficial layer composed of dense fat lobules among numerous fibrous septa and a deeper adipose layer of amorphous, irregular fatty pockets. In the thigh, a superficial fascia analogous to Scarpa's fascia in the abdomen separates these two layers from one another.¹⁰ The abdominal wall fat is well compartmentalized by Scarpa's fascia into superficial and deep layers. The superficial layer is further subdivided into two layers separated by Camper's fascia. The loosely packed deeper layer contains a larger proportion of the subcutaneous fat in the abdominal, gluteal, and thigh regions and is responsible for the unaesthetic bulges associated with weight gain.⁹ The superficial fascial system, in addition to surrounding the superficial fat layer, sends elements through the deep compartment attaching to the investing fascia of the underlying musculature. These extensions become dense at the zones of adherence, where the superficial subcutaneous plane is adherent to the underlying muscle fascia. These zones exist where there is a minimal or no deep fat layer and the superficial layer and its overlying dermis are thin. These zones are therefore more susceptible to contour deformities; they include the gluteal crease, lateral gluteal depression, middle medial thigh, inferolateral iliotibial tract, and distal posterior thigh (Fig. 3).¹¹

These underlying zones of adherence accentuate localized fat deposits between them. In the trunk, men tend to accumulate weight in the flank, the area immediately superior to the iliac crest, whereas women tend to carry excess fat over the iliac crest area. This difference is due in part to the sexually specific locations of the zones of adherence. In men, a zone of adherence lies along the iliac crest and defines the inferior margin of the flank. In women, this zone lies within the gluteal depression overlying the greater trochanter, allowing a cascade of fat to occur over the iliac crest.

RADIOLOGICAL STUDIES

Several studies evaluating adipose anatomy have been performed using magnetic resonance imaging (MRI) to compare obese and

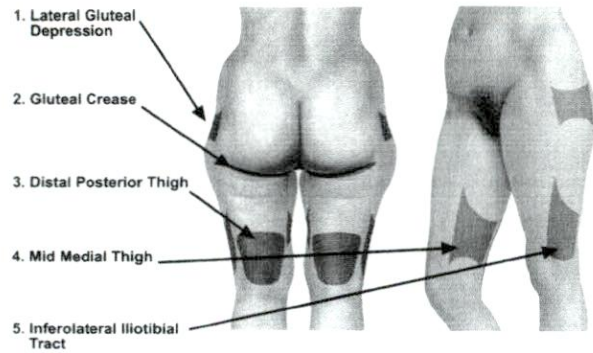


FIG. 3. The zones of adherence are marked in red. They are more susceptible to superficial contour depressions and deformity. The zones consist of the gluteal crease, lateral gluteal depression, middle medial thigh, inferolateral iliotibial tract, and distal posterior thigh.

lean patients.^{2-5,12,13} MRI precisely measures regional fat differences in subcutaneous and internal fat stores without ionizing radiation.¹² In athletic women, the highest amount of total fat to total volume when looking at axial cross sections occurs in the medial femoral fat pocket at the initial cleavage of the thighs.¹³ This subcutaneous fat thins as it moves more distally down the thigh. It then thickens again medially and laterally at the level of the knee. This illustrates the three lower adherence zones: middle medial thigh, distal posterior thigh, and inferolateral iliotibial tract.⁵ An MRI obtained of the lower extremities of a patient with lipodystrophy shows these relative increases and decreases in the subcutaneous fat deposits as the scan moves across these adherence zones (Fig. 4).

CLINICAL APPLICATIONS: IMPORTANCE OF ADHERENCE ZONES IN CIRCUMFERENTIAL LIPOSUCTION

The majority of liposuction is focused on the surgical middle or deeper adipose layer rather than the superficial layer.⁷ Routine liposuction of the superficial adipose layer should be avoided because of the increased risk of contour irregularities, skin dimpling, waviness, hyperpigmentation, and burns. The key element in avoiding postoperative deformity in circumferential liposuction is preoperative marking of the five zones of adherence. No liposuction is done in these areas in most patients; however, it may be beneficial in cases of circumferential large volume liposuction (>5 liters of total lipoaspirate removed). If one performs liposuction in these areas, one should use small (<3.0 mm) cannulae with a low vacuum.

It is the superficial layer that provides the dense matrix for the overlying skin contour and is so important to preserve. It is essential to emphasize the importance of using smaller cannulae (≤ 3.0 mm) superficially and larger ones (3.7 to 4.6 mm) only in the deeper layers,¹⁴ especially when performing circumferential body contouring. All patients undergo a three-phase liposuction procedure, as previously discussed.^{7,11} We use a superwet technique (1:1) of infiltration on all patients and general endotracheal anesthesia.

If the patient has thick fat, large-volume ultrasound-assisted liposuction is begun using a 5-mm, round-tip cannula approximately 35 cm long. The fat layers are treated in a radial

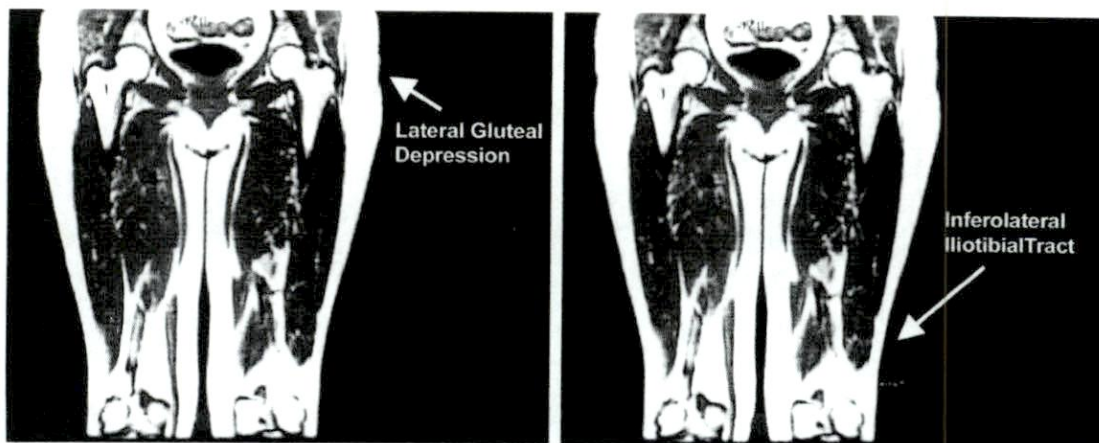


FIG. 4. A coronal MRI through the thigh. The subcutaneous fat thins as it moves toward the foot. The zones of adherence occur where the superficial subcutaneous plane is adherent to the underlying muscle fascia. (Left) Lateral gluteal depression adherence zone. (Right) Iliotibial tract adherence zone.

fashion from superficial to deep (Fig. 5). Slower parallel strokes are used throughout the anatomic areas. The cannula is moved slightly faster in the superficial layer than in the intermediate or deep layers to avoid injury to the overlying skin. The nondominant hand is used to palpate the depth and position of the cannula. The skin should never be grasped and held around the cannula when using the ultrasonic method. This is in contrast to suction lipectomy. The cannula tip should be kept at least 1 to 1.5 cm deep to the dermis. Useful guidelines for determining the clinical end

point of ultrasound-assisted liposuction are the loss of tissue resistance with cannula movement and the presence of blood in the aspirate.^{7,11}

The final phase (evacuation) is done using a standard 3.0- or 3.7-mm suction cannula at 60 to 70 percent of the maximum vacuum suction for evacuation and final contouring of the treatment area. This begins at the dependent deep layer and progresses to the superficial level to facilitate the removal of emulsified fat using progressively smaller cannulae (Fig. 6).

The dense, fibrous fat of the lateral thighs, "banana roll," posterior medial thigh, and but-

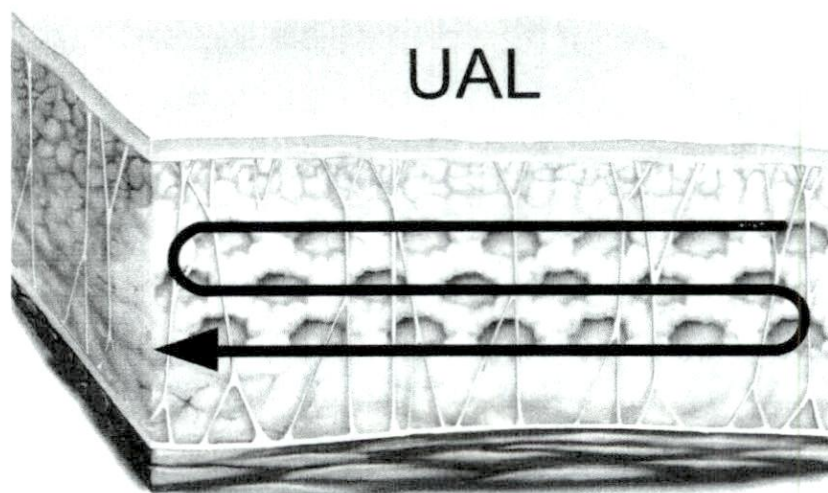


FIG. 5. Ultrasound-assisted liposuction is performed in a radial fashion from superficial to deep. Parallel strokes are used throughout to provide for uniform middle fat layer removal (this is a key element for optimizing results in circumferential body contouring).

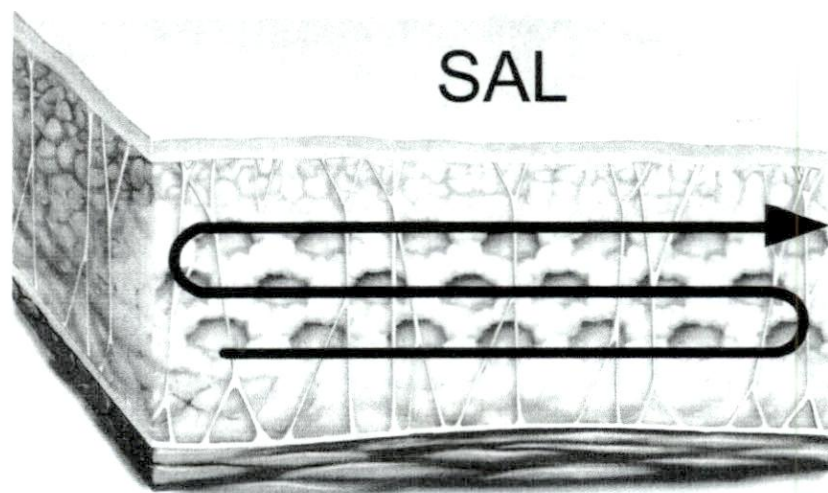


FIG. 6. The final phase of suction-assisted lipectomy (evacuation) is performed from deep to superficial using small cannulae as the superficial compartments are approached.

tocks responds well to ultrasound-assisted liposuction. The anterior medial thigh and anterior thigh respond best to combined ultrasonic and suction-assisted techniques, which will achieve true circumferential body contouring (Fig. 7).

The zones of adherence in the buttocks and thighs should be avoided during liposuction. These zones should be marked on the patient preoperatively because they become more difficult to identify after wetting solution infiltration, and less wetting solution (1:1) is infused into these areas. Of all the zones, the most important is the gluteal fold. This zone is inviolate. Neither ultrasound- nor suction-assisted lipectomy should be performed across this crease. Liposuction parallel rather than perpendicular to the gluteal fold may prevent the crossing of this zone.⁷ Intrusion into these zones may lead to asymmetries and to loss of the gluteal fold or double gluteal fold deformity. Other defects similar to the contour deformities described with liposuction of the superficial adipose layers can occur in these zones.

CASE REPORTS

Case 1: Primary Lipodystrophy

A 42-year-old woman presented with central truncal lipodystrophy, minimal skin laxity, a poorly defined gluteal fold, and noticeable bulging above the iliac crests, hips, superior buttocks, and superomedial thighs. The patient underwent circumferential liposculpture with ultrasonic followed by suction-assisted lipectomy using the techniques described above. A total volume of 4500 cc of lipoaspirate (combined ultrasound and suction) was removed through two lateral gluteal incisions and two inguinal incisions. The total operating time was 2.5 hours. Photographs from the 2-year follow-up are shown in Figure 7.

Case 2

A 32-year-old woman presented with isolated lipodystrophy of the lower abdomen, hips, and anterior thighs. The patient underwent circumferential liposculpture with ultrasound- and suction-assisted lipectomy through two lower abdominal incisions, two lateral groin incisions, two lateral superior gluteal incisions, and an upper flank incision. These are no longer used routinely because most flank contouring can be done through the lateral gluteal incision. A total of 3600 cc of lipoaspirate (combined ultrasound and suction) was evacuated. A 3-year postoperative result is shown in Figure 8. The total operative time was 2 hours.

Examples of contour defects and their treatment are given in the next two cases.

Case 3: Secondary Lipodystrophy Problem

A 35-year-old woman who had undergone previous traditional suction-assisted lipoplasty presented with complaints of

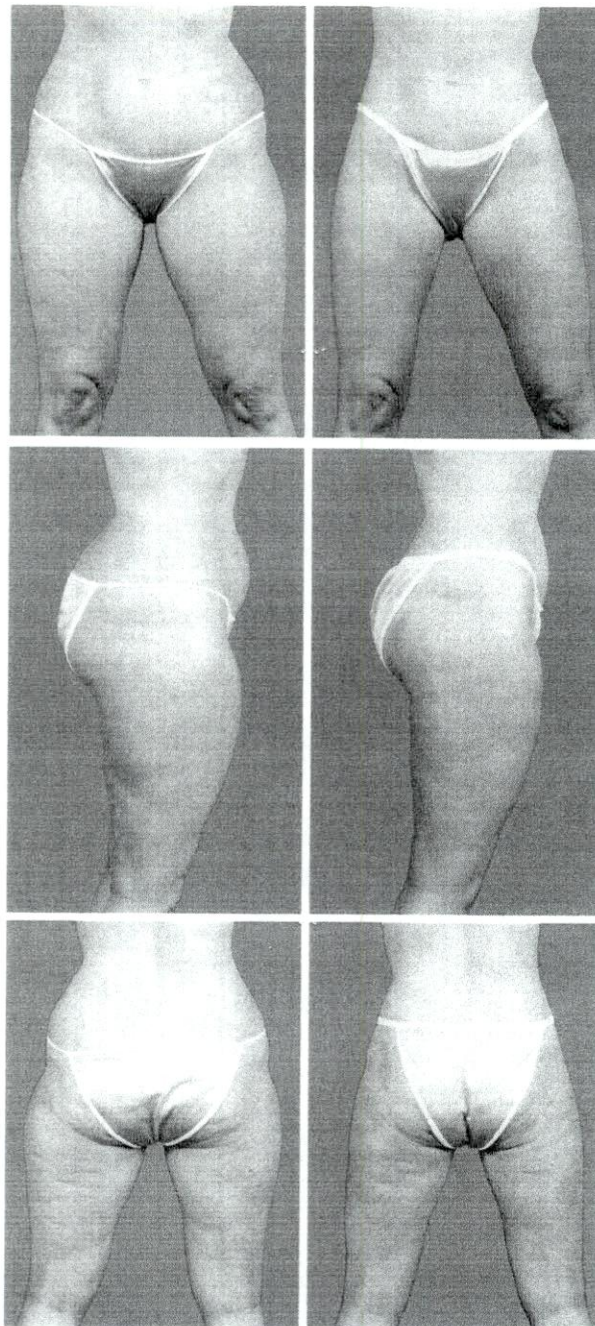


FIG. 7. (*Left*) This patient represents the classic gynoid pattern of fat distribution. She presents with lipodystrophy at the level of the hips, lateral thighs, anterior thighs, and superior buttocks. (*Right*) By 24 months postoperatively, the patient shows an improved circumferential body silhouette, with a concavity at the waist followed by a single convexity over the hips blending into the thigh area (avoidance of masculinization of the lateral thigh area).

bilateral contour irregularities of the gluteal thigh region (the right was greater than the left). These lateral gluteal depression adherence zones and gluteal folds had been violated during the initial liposuction procedure. The deformity consisted of a hollow in the lateral gluteal depression and

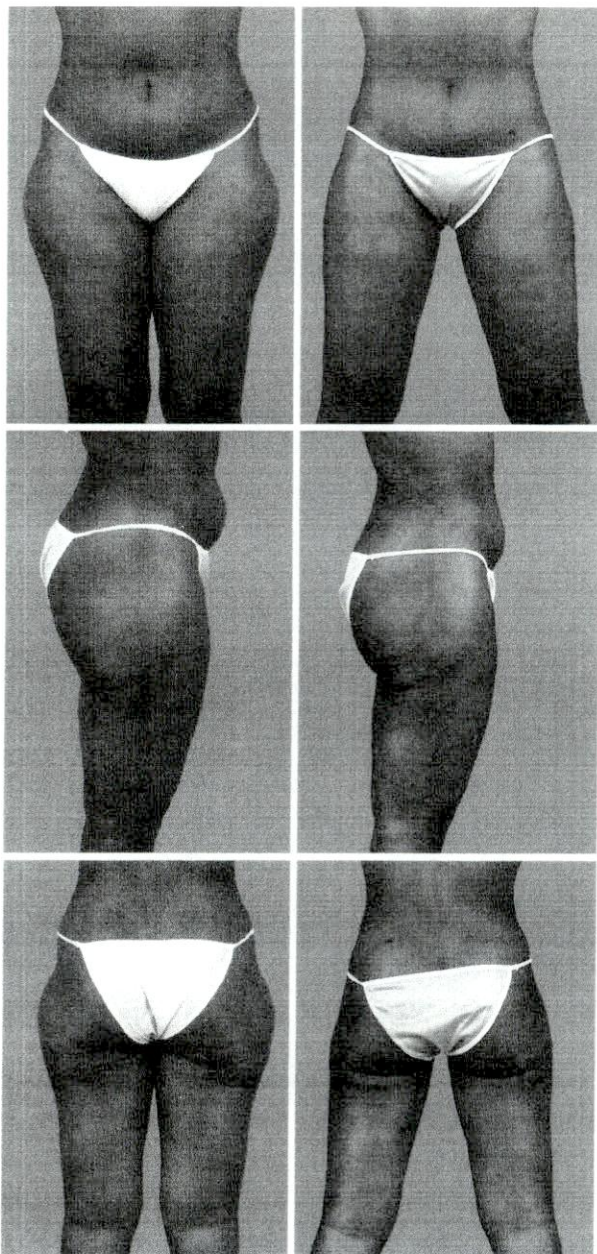


FIG. 8. (Left) The patient presented with isolated lipodystrophy of the lower abdomen, hips, and anterior thighs. She underwent circumferential liposculpture with ultrasound-assisted and suction-assisted lipectomy, which resulted in a more natural-appearing silhouette at 3 years postoperatively (right).

destruction of the native gluteal fold, with creation of a double gluteal fold deformity. Partial repair of this deformity consisted of a combination of traditional small-canula (3.0 cm) liposuction at the perimeter of the depressions to improve the transition into these areas and autologous fat grafting for filling the defect. This patient received 240 cc of injected fat in the right buttock area and 180 cc in the left. Because this patient had a paucity of residual fat, she achieved only partial correction of the deformity. All the harvested fat was reinjected immediately after harvesting with a 3.0-mm

canula in 30-cc increments. No fat centrifuging was done, and each area was overcorrected by 70 to 100 percent (Fig. 9).

Case 4: Secondary Lipodystrophy Problem

A 46-year-old woman underwent body-contouring liposuction approximately 1 year before presentation. She had a significant postoperative deformity involving her thighs circumferentially, with palpable tensor fasciae latae. There was dimpling, with grooving and depressions of her posterior and medial thighs (the right was greater than the left). To correct this contour depression of the lateral and posterior thighs, three procedures involving autologous fat grafting were required in a staged approach. During the first operation, 1600 cc of autologous fat was injected into both the posterior lateral and medial thighs. The fat was harvested and reinjected as discussed in case 3. The fat was injected through multiple ports in a cross-radial fashion to optimize contour

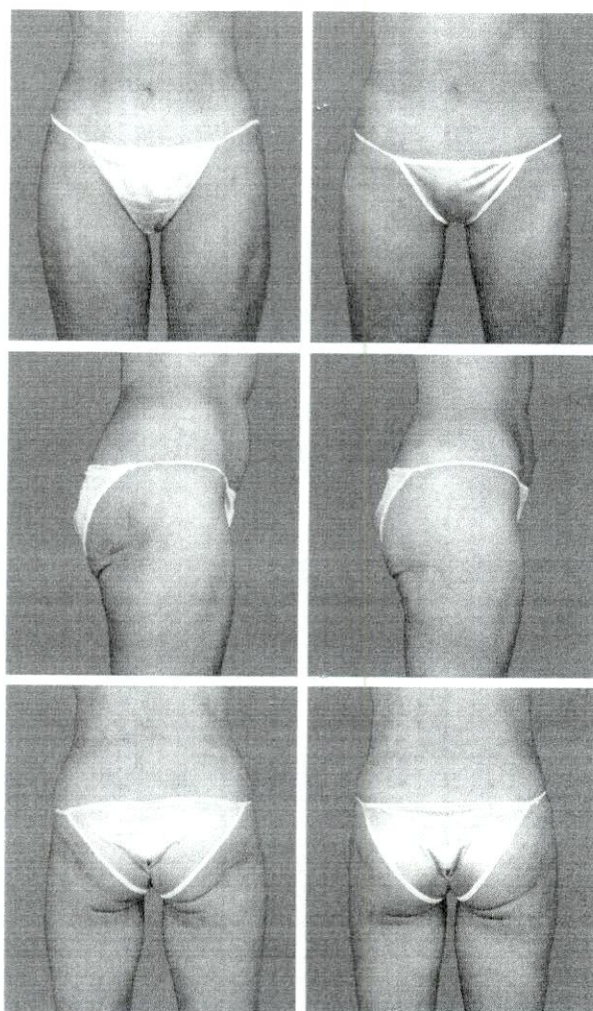


FIG. 9. (Left) Contour irregularities after liposuction are depicted with violation of two adherence zones: (1) loss of a lateral defined gluteal fold and (2) contour depression of the lateral gluteal depression between adherence zones (the right greater than the left). (Right) The patient underwent a second body contouring with autologous fat injections for partial correction of the deformity. She is shown 8 months postoperatively.

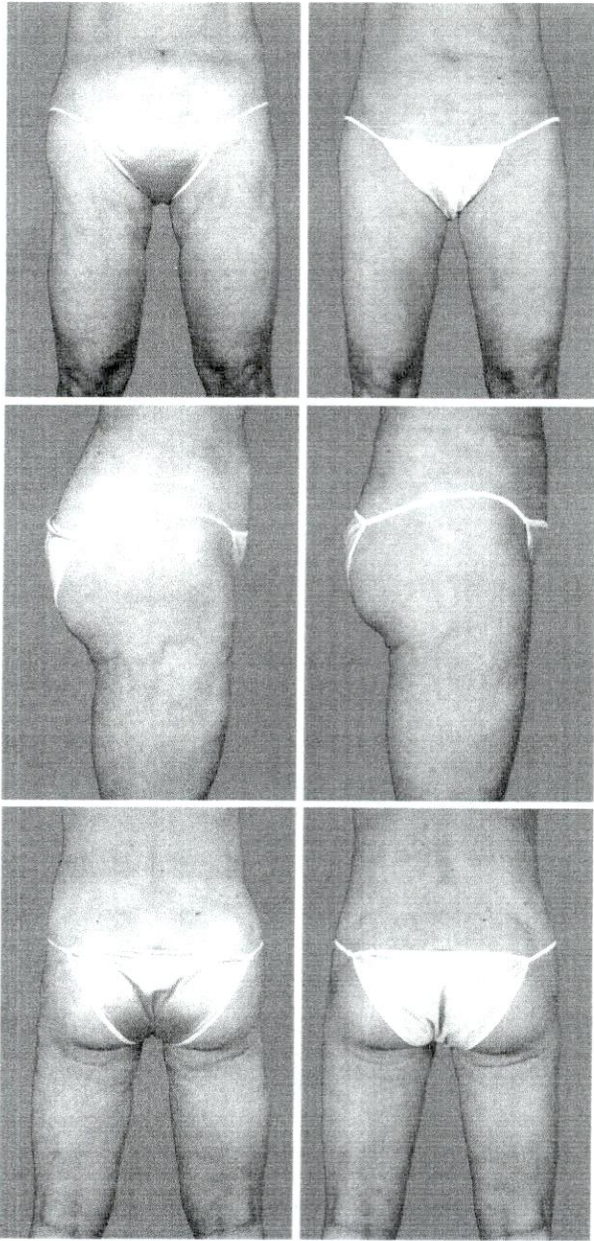


FIG. 10. (Left) Circumferential contour deformities after liposuction, especially in the medial and lateral thighs, are shown. Note the significant contour depression deformity along the right lateral thigh and the multiple concavities along the left hip and thigh. (Right) The patient is shown 6 months after a 3-stage body contouring corrective procedure using autologous fat reinjection (> 4000 cc) to partially correct this difficult contour deformity.

and symmetry. Four months later during the second operation, an additional 1460 cc of fat was harvested from the superior buttocks and abdomen and injected into the residual deformities of the lateral and anterior thighs and posterior/inferior thigh. After an additional 6 months, approximately 600 cc of fat was required to correct the right medial and posterior lateral thigh areas. Similarly, 400 cc of fat was required on the left. After each fat injection, a roller was used

to smooth out residual irregularities. Overall, this patient required more than 4000 cc of autologous fat for grafting (done in 3 operative sessions over a 12-month period) to partially correct these difficult contour deformities (Fig. 10).

DISCUSSION

Recreating an improved body silhouette is accomplished using a circumferential approach to the body's subcutaneous fat stores. A three-dimensional understanding of fat deposits and of their relationship to the underlying muscle units and overlying skin is essential in producing consistent aesthetic results. Failing to take into account the fact that the subcutaneous fat depth is not uniform throughout the trunk and lower extremities or failing to understand the importance of recognizing the five adherence zones will lead to inadequate removal of fat in the deeper deposits and over-resection in the shallower areas. This article emphasizes the existence of these shallower areas and identifies five zones where the subcutaneous fat remains adherent to the underlying muscle fascia and, therefore, becomes more susceptible to over-resection and contour deformities in liposuction.

Postliposuction contour irregularities occur most often in the medial and lateral thighs.¹⁵ Understanding the presence of these adher-

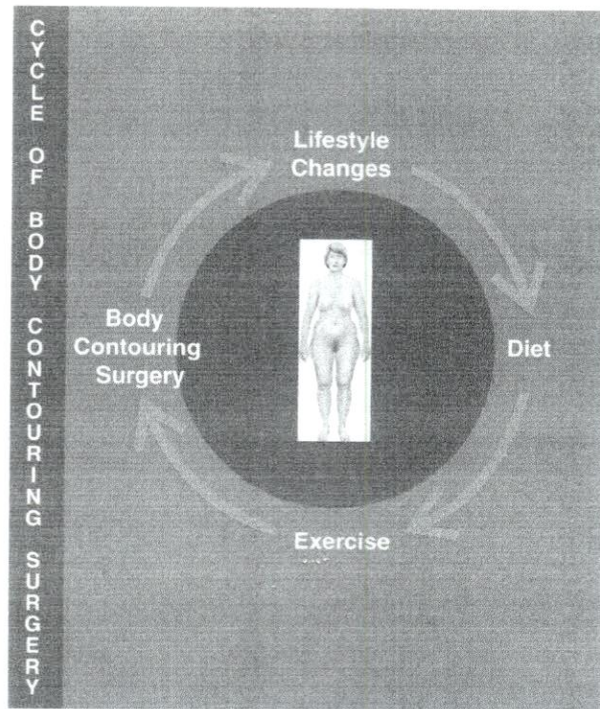


FIG. 11. The cycle of body contouring surgery, emphasizing the role of diet, exercise, and lifestyle changes to obtain consistent, long-term results with liposuction.

ence zones and using smaller cannulae throughout these zones only when necessary is paramount in preventing irregularities. These zones were hinted at in earlier anatomic studies.⁹ However, it was the areas between these zones that were emphasized in the evacuation of fat. This remains true; however, an emphasis on avoiding deep suctioning between these areas of deep fat (i.e., zones of adherence) is necessary to prevent concavities, dimpling, and other localized contour defects. The progression from larger cannulae in the deeper layers of fat to smaller cannulae as one approaches the skin surface during evacuation allows for improved results.

Sex-specific regional differences in fat distribution should be taken into consideration during liposuction as well. In particular, the waist-to-hip ratio approximates 1 in middle-aged men and 0.87 in women.¹⁵ The ratio in the ideal female figure is 0.75.¹⁵ Therefore, women require more sculpting at the waist region than men. This is more important if they have had significant weight loss. It is the body's reliance on visceral fat stores during weight loss and dieting that creates uneven distribution of subcutaneous fat. Patients should be educated regarding the fact that although weight gain occurs in a uniform fashion throughout the body, the converse of this is not true. Fat deposits will remain in the hips and buttocks region.

In conclusion, the key points in avoiding post liposuction contour deformities are as follows:

1. Appropriate preoperative marking of the five zones of adherence.
2. A three-dimensional understanding of the fat layers.
3. Understanding that circumferential body contouring provides more uniform results.
4. Systematic use of the three phases of circumferential contouring, specifically:
 - a. Wetting solution infiltration [using the superwet technique (1:1)].
 - b. Suction-assisted lipectomy, evacuation, and body contouring.
 - c. Ultrasound-assisted lipectomy, fat emulsification, and final finesse contouring.

The best body contour results are achieved when using and applying these principles and by having the patient participate completely in

the body contour cycle by changing his/her diet, exercise, and lifestyle (Fig. 11).

Rod J. Rohrich, M.D.

Department of Plastic and Reconstructive Surgery
University of Texas Southwestern Medical Center
5323 Harry Hines Boulevard, E7.210
Dallas, Texas 75390-9132
rod.rohrich@utsouthwestern.edu

REFERENCES

1. Mokdad, A. H., Serdula, M. K., Dietz, W. H., Bowman, B. A., Marks, J. S., and Koplan, J. P. The spread of the obesity epidemic in the United States, 1991-1998. *J.A.M.A.* 282: 1519, 1999.
2. Fowler, P. A., Fuller, M. F., Glasbey, C. A., et al. Total and subcutaneous adipose tissue in women: The measurement of distribution and accurate prediction of quantity by using magnetic resonance imaging. *Am. J. Clin. Nutr.* 54: 18, 1991.
3. Hendler, R. G., Welle, S. L., Statt, M. C., Barnard, R., and Amatruda, J. M. The effects of weight reduction to ideal body weight on body fat distribution. *Metabolism* 44: 1413, 1995.
4. Ross, R. Magnetic resonance imaging provides new insights into the characterization of adipose and lean tissue distribution. *Can. J. Physiol. Pharmacol.* 74: 778, 1996.
5. Ross, R., Leger, L., Morris, D., de Guise, J., and Guardo, R. Quantification of adipose tissue by MRI: Relationship with anthropometric variables. *J. Appl. Physiol.* 72: 787, 1992.
6. Illouz, Y. G. Body contouring by lipolysis: A 5-year experience with over 3000 cases. *Plast. Reconstr. Surg.* 72: 591, 1983.
7. Rohrich, R. J., Beran, S. J., and Kenkel, J. M. *Ultrasound-Assisted Liposuction*. St. Louis: Quality Medical Publishing, 1998.
8. Goss, C. M. (Ed.). *Gray's Anatomy*, 30th Ed. Philadelphia: Lea & Febiger, 1985.
9. Markman, B., and Barton, F. E., Jr. Anatomy of the subcutaneous tissue of the trunk and lower extremity. *Plast. Reconstr. Surg.* 80: 248, 1987.
10. Lockwood, T. E. Superficial facial system (SFS) of the trunk and extremities: A new concept. *Plast. Reconstr. Surg.* 87: 1009, 1991.
11. Rohrich, R. J., Beran, S. J., Kenkel, J. M., Adams, W. P., Jr., and DiSpaltro, F. Extending the role of liposuction in body contouring with ultrasound-assisted liposuction. *Plast. Reconstr. Surg.* 101: 1090, 1998.
12. Abate, N., Burns, D., Peshock, R. M., Garg, A., and Grundy, S. M. Estimation of adipose tissue mass by magnetic resonance imaging: Validation against dissection in human cadavers. *J. Lipid Res.* 35: 1490, 1994.
13. Gerard, E. L., Snow, R. C., Kennedy, D. N., et al. Overall body fat and regional fat distribution in young women: Quantification with MR imaging. *A.J.R. Am. J. Roentgenol.* 157: 99, 1991.
14. Mladick, R. A. Circumferential "intermediate" lipoplasty of the legs. *Aesthetic Plast. Surg.* 18: 165, 1994.
15. Thomas, E. L., Saeed, N., Hajnal, J. V., et al. Magnetic resonance imaging of total body fat. *J. Appl. Physiol.* 85: 1778, 1998.